

The Morphology of Hormone Induced Structural Changes in the Female Breast

ROLAND BÄSSLER

With 26 Figures

Table of Contents

I. Introduction	2
II. Development	3
1. Embryology of the Mammary Gland	3
2. Intrauterine Sexual Dimorphism	5
3. Development after Castration by X-Ray	5
4. Induction of Deformities by Hormones	5
5. Effect of Anti Androgens	6
III. Growth and Cytomorphology	7
1. Biometry of Normal Glandular Growth	7
2. Autoradiography and Biochemistry of the Mode of Proliferation of Epithelial Cells	8
3. Morphology of Proliferating Glandular Epithelium	11
IV. Effects on the Mammary Gland of Experimental Administration of Hor- mones	16
Ovarian Hormones	16
1. Oestrogen	16
2. Progesterone	23
3. Combined Action of Oestrogen and Progesterone	24
4. Histochemistry of the Connective Tissue During Hormone Action	27
5. Histochemical Enzyme Model	30
6. Electron-Microscopic Morphology of the Hormonally Stimulated Mam- mary Gland	32
Hormones of the Pituitary	38
1. Somatotropin (STH)	38
2. Adrenocorticotropin (ACTH)	39
3. Extract of the Anterior Lobe of the Pituitary	40
4. Transplants of the Anterior Lobe of the Pituitary	40
5. Mammogenic Effect of Transplanted Pituitary Tumours	41
6. Prolactin and the Morphology of the Pigeon Crop Test	41
7. Oxytocin	45
a) Galactokinetic Effect	45
b) Galactopoetic Effect	48
Hormones of the Adrenal Cortex	49
Testosterone	50
Thyroxin	52

Parathyroid Hormone and AT 10	54
Insulin	56
Relaxin	57
Summery	57
V. Pathology of Effects of Hormones on the Human Mammary Gland	57
1. Pathomorphology of the Lobules of the Gland	58
2. Morphology and Function of the Intralobular or Mantle- and Circum- lobular or Supporting Connective Tissue	60
3. Aetiology and Pathogenesis of Benign Dysplasias	63
4. Galactorrhoea in the Human Mammary Gland	65
References	67

I. Introduction

Many morphological, physiological, and biochemical investigations have contributed to the classification of the endocrine regulatory mechanisms responsible for development and function of the mammary gland. These studies received their crucial impetus when the synthesis of the sex hormones had been achieved and from their experimental use. The history of the use of these drugs is thus also the history of the concept of control of the mammary gland by hormones. The individual factors and combinations of factors responsible for the normal growth of the glandular structure of the mammary gland, for its secretory function, and for its pathomorphology have been elucidated by systematic studies. The laws that have been discovered have led to a classification of reaction types and have made it possible for experimental observations to be compared with the responses of the human mammary gland. Current concepts of quantitative morphology and endocrinology have broadened our understanding of the mechanisms of the action of sex hormones on the mammary gland. Generally valid concepts of hormonal regulation of growth and metabolism have been derived from this.

The structural changes of the mammary gland, discovered in experimental work and reported initially in the gynaecological and anatomical literature, are now largely objects of research in the fields of endocrinology, galactology, and biochemistry. This explains why the literature on the subject is so dispersed. Recently, new aspects of fundamental research have arisen, chiefly concerning the sites of hormone action and intracellular enzyme induction by hormones.

It is my aim to present the essentials of the current views on changes of structure due to hormones, based on the reviews of the physiology by FOLLEY (1956), STEINBECK (1969), of the cytomorphology and anatomy by TURNER (1952), DABELOW (1957), MAYER and KLEIN (1961), the pathology of the breast by SCHULTZ (1933), GESCHICKTER (1948), HAAGENSEN (1956), GÖGL and LANG (1957), CUTLER (1961), and on the voluminous monograph by KON and COWIE (1961). Special consideration will be given to the results of electron-microscopic and histochemical investigations. The stress will be on results of experimental research, including some of the morphological aspects of

dysplasia of the human mammary gland. Problems of experimental tumour pathology and of lactation will be covered only in so far as they are of importance for the explanation of the action of endocrines on the metabolism.

II. Development

1. Embryology of the Mammary Gland

The development of the mammary gland is essentially the same in monotremes, marsupials, and placentalia, independent of whether there are one or several pairs of glandular primordia. The embryology of the human mammary

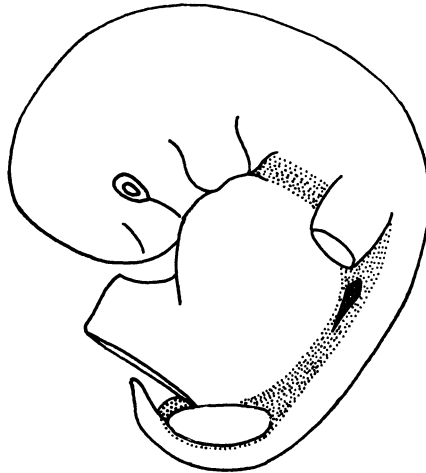


Fig. 1. Extent of galactic band (dotted) and milk-ridge (black line) in a human embryo, 11½ mm long (32/33 days old). (After SCHMITT, 1898)

gland is similar to this phylogenesis, as the older descriptive morphological studies of KOELLIKER (1852), REIN (1882), BROUHA (1905), BERK (1913), LUSTIG (1915), and v. EGGELING (1927) have shown. Reconstructions by LUSTIG (1915), BROMAN (1927), and SPULER (1930), and histological studies by NEUMANN and OING (1929), THÖLEN (1949), and GRAUMANN (1950) have demonstrated that the glandular primordium differentiates continuously. This differentiation starts in human foetuses in the fifth week of germination with an epithelial thickening of the lateral wall of the trunk. It then passes into a phase of the development of individual primordia (Fig. 1). The following phases of development are distinguished:

1. *Milk-streak* (H. SCHMIDT, 1897; H. SCHMITT, 1898). A thickened band of epithelium, 2—4 layers high, develops at the lateral wall of the thorax and abdomen in human foetuses of 6—10 mm vertex-breach length (THÖLEN, 1949). This galactic band is the site of supernumerary primordia.

2. *Milk-line or Milk-ridge* (BROUHA, 1905; LUSTIG, 1915). The epithelium widens to 4—6 layers in the area of what later is to become the site of individual primordia, and the galactic band involutes, in foetuses measuring 9—15 mm (Fig. 1).

3. *Stages of hillock-, bud-shaped, or globular individual primordia.* The cell proliferations developing from the cranial part of the milk-ridge form small prominent hillocks, and then become depressed buds or globules in the mesenchyme. This happens during the 3rd and 4th months and is combined with an increase of local mesenchymal cells.

4. *A cone- or flask-shaped growth sector* with elongation of the epithelial primordium develops. Superficial desquamations of the epithelium cause the nipple groove to appear into which later the lactiferous tubules open.

5. The solid *epithelial proliferations* develop lumina in the 5th and 6th lunar months (THÖLEN, 1949). The primordium enlarges, and in foetuses of 15 cm length extends to the subcutis. At the end of pregnancy the peripheral ends of the proliferations enlarge and form terminal vesicles, usually filled with secretion (DABELOW, 1957).

This morphological analysis of the development of the mammary gland has been broadened by experimental work on embryos relating both to the initial phases of development (BALINSKY, 1950a, b; GRAUMANN, 1950; HARDY, 1950) and to the problems of sexual dimorphism and the induction of deformities by hormones (RAYNAUD, 1961).

The bud of the gland during the 3rd—5th foetal months consists of polygonal cells with chromatin-rich nuclei and is surrounded by a highly prismatic layer of cells (SPULER, 1930; HUGHES, 1950). — BALINSKY (1950) distinguished a phase of cell aggregation, a rest phase, and a phase of growth during proliferation. He made the notable observation that the mitosis index in the primordium was lower than in the surrounding epithelium. He concluded that the buds were formed by cell migration. The individual primordia, which are independent of each other, are formed by a mesenchymal inductor, the RNA-rich cells of which are supposed to be derived from Wolff's duct; they slowly lose their nucleic acid content. — GRAUMANN (1950) interpreted these interrelations to the surrounding mesenchyme during the budding stage as being due to a displacement of tissue fluid, because the epithelial cells of the budding stage are large and transparent and because the mesenchymal cells become denser.

2. Intrauterine Sexual Dimorphism

The question of the dependency of the embryonal development of the mammary gland on hormones has been investigated experimentally in explantates and histomorphologically:

According to BALINSKY (1950) skin explantates of ten days old mouse embryos had a globular stage of glandular development, which additions of hormone to the culture medium did not influence. — Similarly, HARDY (1950) had described developmental stages of the mammary gland in explantates of the chest wall of 10—13 days old mouse embryos that corresponded to the developmental stage of the 7th day. These observations indicate retardation, but neither inhibition nor stimulation.

The dimorphous histogenesis of the mammary gland appears in the mouse only after the 15th day of intrauterine development. The primordia in *female animals* are characterised by a narrower neck between bud and epidermis, with involution on the 16—17th day. This leads to the incorporation of the bud into the epidermis (RAYNAUD, 1961). The *male primordium*, on the other hand, shows a stronger circular mesenchymal reaction, which is of importance for further development and may be influenced by foetal testicular hormone (RAYNAUD, 1947; RAYNAUD, 1961) (Figs. 2a, b, c).

The results of these experimental studies indicate that the *early stages* (up to the 10—12th day) of the mammogenesis in the mouse are *independent of specific hormones*. The glandular development between the 12th and 14th day is in a highly *sensitive phase*, which has disappeared by the 15th day of development. The following observations provide evidence for this:

3. Development after Castration by X-Rays

When the gonads are treated with x-rays of 100,000—120,000 r on the 13th day, female foetuses show a degree of development of the primordium of the mammary gland that corresponds to that of the control animals. The glands of male foetuses behaved, on the other hand, like those of the female animals (RAYNAUD and FRILLEY, 1947, 1949; RAYNAUD, 1961). This means that the testes are responsible for the normal course of male development, i.e. separation of the epithelial buds from the epidermis and lack of an areola. — Gonadectomy in both sexes leads to female differentiation, indicating that this is a neutral, non-hormonal type (RAYNAUD, 1961).

4. Induction of Deformities by Hormones

Androgenic. When either pregnant mice or foetuses are injected with testosterone-propionate, the primordium of the mammary gland becomes masculinized (RAYNAUD, 1947a; RAYNAUD and RAYNAUD, 1954, 1961). It is concluded, that androgens normally prevent the development of nipples and extensive formation of mammary tissue in male fetuses (NEUMANN and ELGER, 1967). Sometimes it may cause athelia. Inhibition or lack of the endogenous androgens results in a female organogenesis of the mammary gland (ELGER and NEUMANN, 1966). The development of the gland of female animals is inhibited by androgens.

When *oestrogens* are injected into either mother animals or foetuses the development of both gland and nipple is stimulated. Arrest of mammogenesis in dose-dependency has also been observed, exhibiting as *amastia*, *micro-mastia* or *koilomastia* (pivot nipple) (RAYNAUD, 1947b, 1952). Also, secondary epithelial buds developed from primordia (Figs. 2D, E, F).

Injection of 40—150 mg oestradiol benzoate into the foetus produced 95 % deformities, when the drug had been given on the 12—14th day. On the 15th day the deformity rate was a mere 5 %. Injection into the mothers during the sensitive phase caused in dose-dependency derangements of the primordia:

50 mg oestrogen produced 5 % deformities of the mammary gland, 100—200 mg oestrogen 50 %, and 500—1,000 mg oestrogen 90 % (RAYNAUD and RAYNAUD, 1956).

Injection of *progesterone* (HOSHINO, 1966) in pregnant mice induce in female mice an inhibition in development of the duct system, but not athelia. The reaction in male mice is comparable with effects of anti-androgens. The mammary glands are developed like female mice.

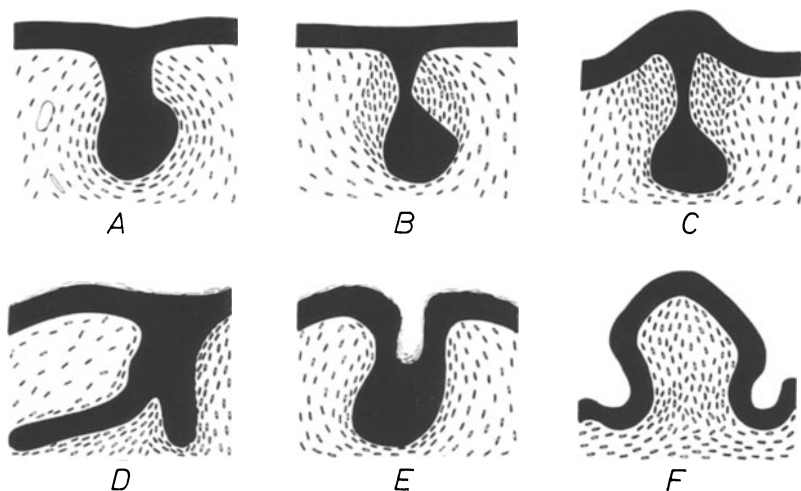


Fig. 2A—F. Schematic presentation of various types of development of the first inguinal glandular primordium of the mammary gland of the mouse (modified after RAYNAUD, 1947, 1961). A Female mouse, 15th day, 17 hours. B Male mouse, 15th day, 17 hours. C Female mouse, 15th day, 16 hours after treatment of the mother with testosterone. Development of narrow neck of the primordial gland and siting of mesenchymal reaction are very similar in B and C. D Female mouse, 18 days, thoracic bud with proliferation of two solid primordia of ducts after injection of oestradiol in foetuses on the 13th day. E Female mouse, 18 days, thoracic primordium after injection of oestradiol (75 mg) on the 13th day with production of an epithelial pocket with desquamated epithelium (coilomastia). F Female mouse, 18 days; suppression of development of mammary gland by injection of 94 mg oestradiol on the 13th day (amastia)

5. Effect of Anti-Androgens

When synthetic gestagenous steroids were studied, a substance with anti-androgenic action was isolated that was called cyproterone acetate (1, 2 α -methylene-6-chloro- Δ 4,6-pregnadiene-17 α -ol-3,20-dion-17 α -acetate). It became thus possible selectively to exclude testosterone in sex differentiation (HAMADA, NEUMANN, and JUNKMANN, 1963; JUNKMANN and NEUMANN, 1964; NEUMANN and ELGER, 1966; ELGER, v. BERSWORDT-WALLRABE, and NEUMANN, 1967). — Cyproterone acetate, when administered into the uterus, caused female differentiation of the mammary gland of male rat foetuses after the 13th day, with extensive epithelial proliferation and formation of an epithelial ridge corresponding to the nipple. This is evidence that *androgens of the foetal testis by themselves may inhibit the development of the mammary gland* (NEUMANN

and ELGER, 1966). — Foetuses that were genetically male, and which had been feminized in utero by anti-androgens, behaved outside the uterus on combined hormone treatment like genetically female animals, began to lactate, and to form nipples (NEUMANN, ELGER and v. BERSWORDT-WALLRABE, 1966).

III. Growth and Cytomorphology

1. Biometry of Normal Glandular Growth

To the investigation of the tissue structure of the mammary gland has now been added the biometrical exploration of the structural changes that occur in the mammary gland under normal and abnormal conditions, resulting in further insights into morphogenesis and dynamics of function.

The earliest accounts of quantitative research are by GARDNER and STRONG (1935), VAN HEUVERSWEYN, FOLLEY, and GARDNER (1939), FOLLEY, GUTKELCH and ZUCKERMAN (1939), and DUBOIS (1944), who had tried to study the growth of the mammary gland semi-quantitatively. RICHARDSON (1947, 1949, 1953, 1966, 1967) further developed these methods. Three quantitative aspects were presented: 1. The relationship between the growth of the mammary gland and the expansion of the body surface area. 2. The analysis of the extent of ramification of the lactiferous ducts, four steps of ramification and proliferation being stipulated (NANDI, 1958, 1959). 3. The determination of the total surface of the mammary gland. The relationship to the expansion of the body surface may be expressed by a formula. According to COWIE (1949), the mammary gland of the rat up to the 21st—23rd day develops isometrically compared with the body surface. Subsequently, growth becomes allometric under the influence of sex hormones and increases 3—5fold. This may be inhibited by ovariectomy. BENSON, COWIE, COX and GOLDZWEIG (1957) determined the volume of glandular tissue when they investigated the induced development of the mammary gland of the guinea pig. The assessment of the total surface of the secretory epithelium was based on a method developed by SHORT (1951) for the determination of the total surface of the pulmonary alveoli. This method has been used by RICHARDSON (1953) for the investigation of the mammary gland of the goat. CHALKLEY (1943) estimated the relative volumes of individual tissue components by relating, under the microscope, the areas of these components in histological sections to a system of specially arranged points. KIRKHAM and TURNER (1954) used biochemical methods for the quantitative assay of the glandular parenchyma. They assessed the increase or decrease of parenchyma by the increase or decrease of the numbers of cell nuclei, which, of course, are in proportion to desoxyribonucleic acid.

These quantitative methods had been used to assess the influence of hormones on the mammary gland and its morphological reactions. This was done by FOLLEY (1952, 1955), FLUX and MUNFORD (1957), BENSON, COWIE, COX and GOLDZWEIG (1957), and v. BERSWORDT-WALLRABE (1958a, b). The last author had studied in lactating mice, using volumetric, karyometric, and statistical methods, the involution of the gland under the influence of oestrogen.

Compared with the number of publications of quantitative studies about the effect of hormones, publications that describe quantitative studies of the structures of the mammary gland under physiological conditions, are sparse: SCHAIRER (1936) had differentiated the cell nuclei of the resting from those of the lactating cells by comparative measurements. WEBER, KITCHELL, and SAUTTER (1955) had determined the volume of the lobules in the mammary gland of the cow and had counted the alveoli of the individual lobules. — MOSIMANN (1957) measured the volume of cell nuclei in the epithelium of the mammary glands of goats and rats, in relationship to the state of function and after administration stilboestrol.

The writer and FLÖRCHINGER (1966a, b) had carried out systematic studies of the histometry of the mammary gland during normal functioning, during experimental galactostasis, and under the influence of an increased fluid supply, when Periston infusions had been given. By contrasting the findings in the periphery and the centre of the gland, of parenchyma and connective tissue, of height of epithelium and width of alveoli, certain correlative data about secretion, fluid transport, and absorption were obtained.

NICOLL'S (1965) experiments have shown that mammary growth has no humoral autoregulation, so that there is no evidence for a feed-back mechanism by substances with mammotropic action. On the other hand, transplantations have indicated that there is a *regulating influence of local fat tissue* on glandular growth.

2. Autoradiographic and Biochemistry of the Mode of Proliferation of Epithelial Cells

Protein and nucleic acid synthesis in the mammary gland is subject to regulation by hormones; at the beginning of pregnancy these synthetic processes increase by several times their resting value. Post partum proliferation of the glandular epithelium is mainly due to prolactin, which regulates the production of cytoplasmatic proteins, DNA-synthesis, and cell proliferation (BALDWIN and MARTIN, 1968). Prolactin and cortisol are needed after hypophysectomy to stimulate RNA- and casein synthesis and the production of glucose-6-phosphate-dehydrogenase. This key enzyme increases 100fold 24 hours post partum; this indicates the shift of carbohydrate catabolism from the Emden-Meyerhof cycle to the oxidative pentose-phosphate cycle (GLOCK and MCLEAN, 1954; RAPOPORT, 1962). The intermediate metabolism is thus regulated to produce NADPH₂ for fatty acid synthesis to provide pentoses for nucleic acid requirements. Metabolic conditions for cell replenishment and cell differentiation are thus created by mammotropic substances.

The mammary gland is subject to hormonal stimulation, and during normal functioning belongs to the group of labile tissue elements, because desquamation in the lumina requires the perpetual replacement of cells. This replacement is done by the basal cells. Mitoses were observed only rarely, amitoses not at all (MAEDER, 1922; JEFFERS, 1935). The division into sequent phases of proliferation and differentiation (ALTMANN, 1966) suggests com-

parison with the endometrium. Proliferation and cellular differentiation of the epithelium are closely related in the mammary gland during pregnancy. Structural differences certainly narrow down as pregnancy goes on, compared with functioning, i.e. lactation, but they remain important, because the specific protein casein is synthesised in the post partum phase only.

According to *autoradiographic studies* the time needed for DNA-synthesis in the nuclei of epithelial cells of the resting mammary gland of C₃H/HeJ mice was 20.7 hours. When the mammary gland was stimulated for three days with oestradiol and progesterone, the S-phase lasted for 10.7 hours (BRESCIANI, 1964) only. After pretreatment for 2—3 weeks the time needed for synthesis was 8.8 hours (BRESCIANI, 1965). These observations demonstrate that ovarian hormones accelerate synthesis of DNA in the mammary gland. Both synthesis and synchronicity of chromosome duplication are affected by the hormones through co-factors. According to JERVELL, DINIZ, and MUELLER (1958) the rate of assimilation of C¹⁴-O₂ into the nucleotides adenine, guanine, and uridine, is increased by oestrogen, before the amount of RNA increases. — From the point of view of cytomorphology this explains the increased chromatin content and the enlarged cell nuclei, which synthesize more protein and RNA, of hormone stimulated mammary glands. This has been demonstrated in model studies of functional nuclear swellings by STÖCKER (1962, 1964), SANDRITTER, FEDERLIN, and PFEIFER (1964). Comparative studies with double thymidine labelling by BANERJEE and WALKER (1967) gave the following results:

Table 1. *Time required for synthesis of DNA in the mammary gland*

Glandular cells of the lactiferous tubules	virgin C ₃ H-mice	20.7 hrs. ^a	S-phase
Pre-lactating breast	8th day of pregnancy	14.1 hrs.	S-phase
Pre-lactating breast	15th day of pregnancy	8.2 hrs.	S-phase
Pre-lactating breast	15th day of pregnancy	9.4 hrs.	S-phase
Lactating breast	2nd day	8.5 hrs.	S-phase
Transplant of pre-lactating breast (15th day)	in virgin mouse	21.5 hrs.	S-phase

^a According to BRESCIANI (1964).

DNA-synthesis in the mammary gland increases 2—3fold during pregnancy and lactation. This is in conformity with the increase of cell reproduction and proliferation, compared with the resting gland. TRAURIG (1967a, b) has shown by autoradiographic studies that the distribution of epithelial proliferations in the mammary gland during pregnancy is bimodal. There is a maximum at the 4th day, at the time of implantation. A second peak on the 12th day coincides with the beginning of progesterone secretion of the placenta of the mouse.

During this phase of development the epithelium of the lactiferous tubules is identical with that of the epithelium of the lobules. During lactation the

greatest number of labelled cells was found on the 2nd and 3rd day (TRAURIG, 1957b) (Fig. 3). During these days the secretory activity of the glandular epithelium also rises, and this is accompanied by enlargement of the terminal

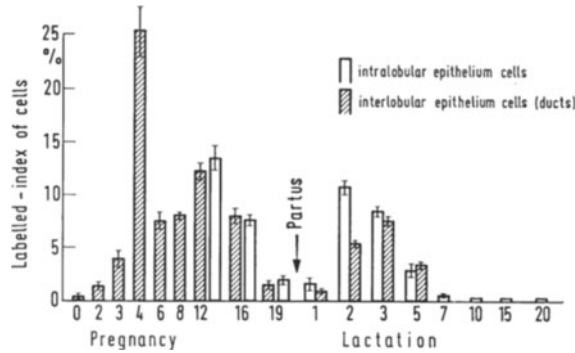


Fig. 3. Summary of autoradiographic examinations with H³-labelled thymidin of epithelial cells of the pregnant and lactating mammary gland of the mouse. (Modified after TRAURIG, 1967 a, b)

buds of the lobules and formation of alveoli (BÄSSLER und FLÖRCHINGER, 1966a). The number of labelled myoepithelial cells is greatest too, on the 2nd, 3rd, and 5th day post partum, thus indicating their ability to proliferate. The fibroblasts of the intra- and interlobular stromas show the same behaviour.

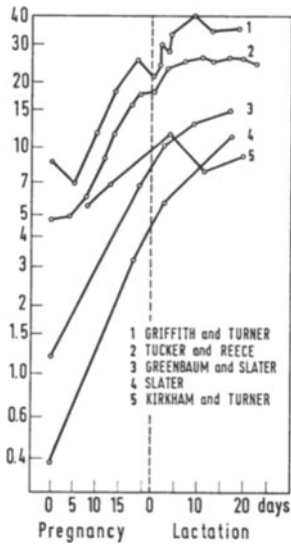


Fig. 4. Summary of rise of DNA in the pregnant and lactating mammary gland according to different authors. (Modified after MUFORD, 1964)

Biochemical studies of the DNA-content of the mammary gland during pregnancy and lactation have demonstrated that nucleic acids rise intensively and continuously, obtaining maximal values within the first 5—8 days of lactation (Fig. 4) (KIRKHAM and TURNER, 1953; GREENBAUM and SLATER, 1957; GRIFFITH and TURNER, 1957, 1961; MOON, 1962; NELSON, HEYTLER and CIACCO, 1962; TUCKER and REECE, 1963 a, b, c; MUFORD, 1964). When lactation lasts as long as 40—60 days, the DNA-content remains constant, whilst RNA decreases. The body weight of the young animal also diminishes (TUCKER and REECE, 1963 b). During involution DNA and RNA greatly decrease within a few days. The effect of oestrogens, administered at this time, is accelerating, that of oestrogens together with progesterone inhibitory (TUCKER and REECE, 1963 c; GRIFFITH and TURNER, 1961 c). — Studies of experimentally induced growth (MOON, GRIFFITH, and TURNER, 1959; TUCKER and REECE, 1963 d) underscore the significance both of the DNA-content as indicator of glandular growth and of the (simultaneous) increase of protein synthesis. —

—

Discrepancies found in autoradiographic observations (TRAURIG, 1967) are due to the manner in which the glandular tissue has been prepared, because the admixture of connective tissue, fat, intramammary lymph nodes, and blood-vessels is usually not taken into account when the tissues are homogenised.

3. Morphology of Proliferating Glandular Epithelium

The epithelium of the lactiferous tubules and of lobules consists of a regular, palisade-type layer of cylindrical surface epithelia and of flat or cubical cells as basal layer (v. EGDELING, 1927; SCHULTZ, 1933; DABELOW, 1957).

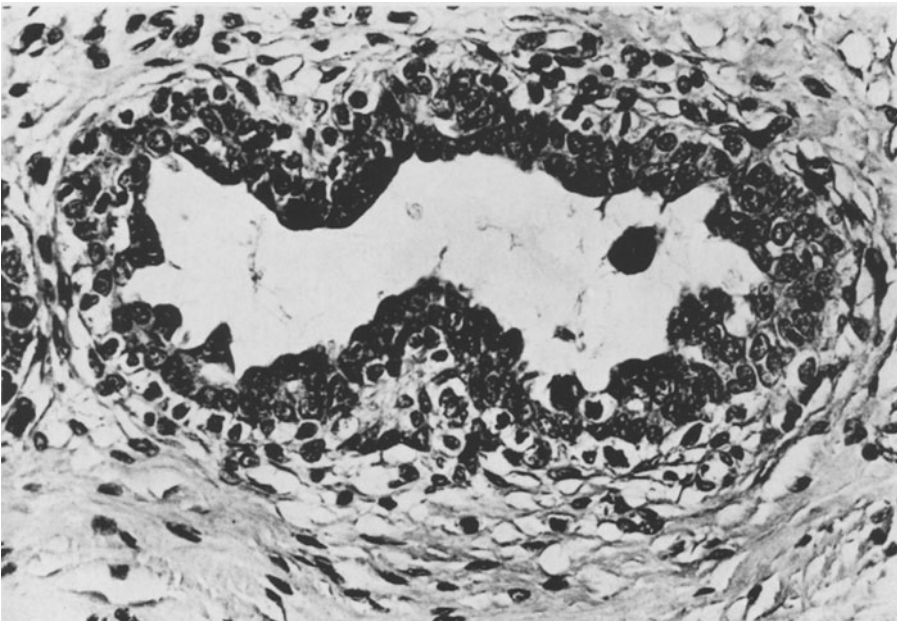


Fig. 5. Duct with considerable proliferation of epithelium and mitoses in gynaecomastia. Superficial cell layer dark, basal cell layer clear. Proliferation of histiocytes and fibroblasts in mantle tissue. Bouin, paraffin, enlargement 230 ×

The height of the epithelium is related to the width of the lactiferous tubules and lobules. Some of the basal cells contain myofilaments and constitute the system of myoepithelial cells. In the lumina of human and animal mammary glands droplets of a protein-containing secretion are often found, this being a product of apocrine secretory processes. The sex hormones, especially oestrogen, stimulate the glandular epithelium to proliferate. The epithelium becomes multilayered and forms buds and papillae, contingent upon the intensity of the hormonal stimulation. The epithelial cells differentiate more than normally into large clear cells and basophilic dark cells, the latter being situated superficially and surrounding the lumen (Fig. 5). The cells change further in that the nuclei enlarge, chromatin increases, and large nucleoli and mitoses emerge. The intracanalicular buds also consist of these cells. In the

basal row of cells highly transparent cell plasma structures may be seen. GRAUMANN (1953) called these cells in the male mammary gland "clear epithelia", and VOGLER (1947) mentioned "clear cells" in Feyrter's sense.

When seen under the light microscope, epithelial proliferations are characterized by an irregular increase of cell layers, which may protrude into the lumen as individual cell buds or as groups of cells with small papillae. These proliferations reveal themselves, as in animal experiments, under the influence,

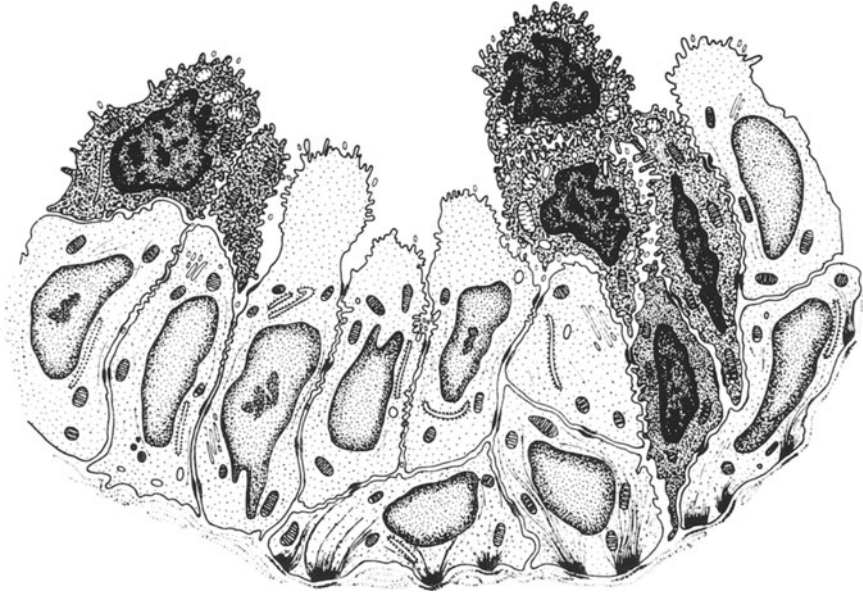


Fig. 6. Schematic representation of proliferation of cells in a duct in gynaecomastia, according to electron-microscopic findings. The clear cells contain filaments, which insert basally on hemidesmosomes. Superficially they form budshaped processes of the cytoplasm. — Dark cells and cells with intercellular dehiscences and regressive changes are also present (superficial cells)

of exogenous or endogenous oestrogen, as evidenced by the occurrence of gynaecomastia after application of oestrogen (Fig. 5): the proliferating epithelium consists of a basal layer of transparent cells with mitoses, which are covered by several layers of basophilic epithelia, and which protrude as pseudopapillary cell groups into the lumen. Individual cells desquamate, and there is a little secretion. In the stroma loosening and cellulation are seen. — According to CASPERSSON (1950) the basophilia of the cytoplasm of the dark superficial cells indicates a large amount of RNA and of ergastoplasm as morphological expression of intensive protein synthesis. —

This microscopical picture may be contrasted with a schematic representation of electron-microscopic findings in gynaecomastia. BÄSSLER and SCHÄFER (1968, 1969a) claim that the shape and structure of clear basal cells and basophilic superficial cells become evident when hormone induced proliferation (Fig. 6) occurs.

Electron-microscopic examination of the mammary gland and of carcinomas of the mammary gland (HAGUENAU, 1959; HAGUENAU and ARNOULT, 1959) have revealed cell forms that have been divided into A and B types. WAUGH and VAN HOEVEN (1962) have questioned this categorization and have thought the A cells to be artefacts. BUSCH and MERKER (1968) have claimed that the dark (A) cells in carcinomas are the outcome of supravital reactions to the fixing compound. BERGER (1964), on the other hand, still believes in the A-B grouping in fibrocystic mastopathy and in carcinomas. — My own investigations of the cytomorphology of the female and male mammary gland, of gynaecomastia, and of highly differentiated and anaplastic carcinomas have led me to classify the epithelial cells as follows:

1. The *A-cell* is a cell that is rich in ribosomes and therefore appears dark in the electron-microscope (Fig. 7). The nucleus is rich in chromatin and partly lobulated. There is very little ergastoplasm. This type corresponds to the basophilic form in the light microscope. — The isomorphism of this type, the lack of regressive changes, and the siting in groups indicate that these cells are part of the epithelium and occur chiefly under the influence of proliferation. The action of oestrogen on the mammary gland (BÄSSLER and FORSSMANN, 1964) and on the uterus (ROSS and KLEBANOFF, 1967) in experiments seems to show that the high ribosome content of these cells is the response of protein synthesis to stimulation by hormones.

2. The *B-cell* or *Chief cell*, which numerically preponderates, has a clear, transparent cytoplasm, a round or oval nucleus, and smooth cell membranes. These cells are held together in groups by desmosomes, and microvilli occur as differentiation products of the surface of the lumen. They contain fewer ribosomes than A-cells. The chief cells of the normal female and male mammary glands have no or sparse fibrillar cytoplasmic structures, although proliferating cells and tumours often contain filaments of 50—80 Å diameter (Fig. 7).

My own observations have demonstrated that the chief cell is the essential structural element in the acini of female and male mammary gland (BÄSSLER and SCHÄFER, 1969b). Its content of ribosomes and filaments varies greatly, so that this cannot be used as such for the classification of these cells. I believe that the occurrence of filaments and of a dense felt of fibres in the cell plasma is an indication of a differentiation process. The ability of these cells to produce fibres is ubiquitous and is used when the cells proliferate. These cytoplasmic filaments morphologically and dimensionally correspond to those of myoepithelial cells. The fibres in the myoepithelium are denser and contractile. In the chief cells the cytoplasmic fibrils present structures that correspond to tonofilaments as stabilizing structures, as found in other epithelial cells also in the endothelium of lymph and blood capillaries (SCHIPP, 1968). The occurrence of filaments in the cytoplasm does *not justify the designation of all cells that contain fibrils as myoepithelial cells*, because this term includes the ability to contract and a special localization.

Large clear cells that have the morphological properties of chief cells also predominate in the lactiferous tubules and acini of the mammary glands of

rats. In experimental work when sex hormones are given cell forms develop with a variety of para- and metaplasmatic inclusions (compare p. 35).

3. *The myoepithelial cells*, which rest upon the basal membrane as elongated cell bodies (Fig. 8), are regular elements of the excretory ducts, of acini, and of alveoli. The cell nucleus usually protrudes within the cell groups and rests

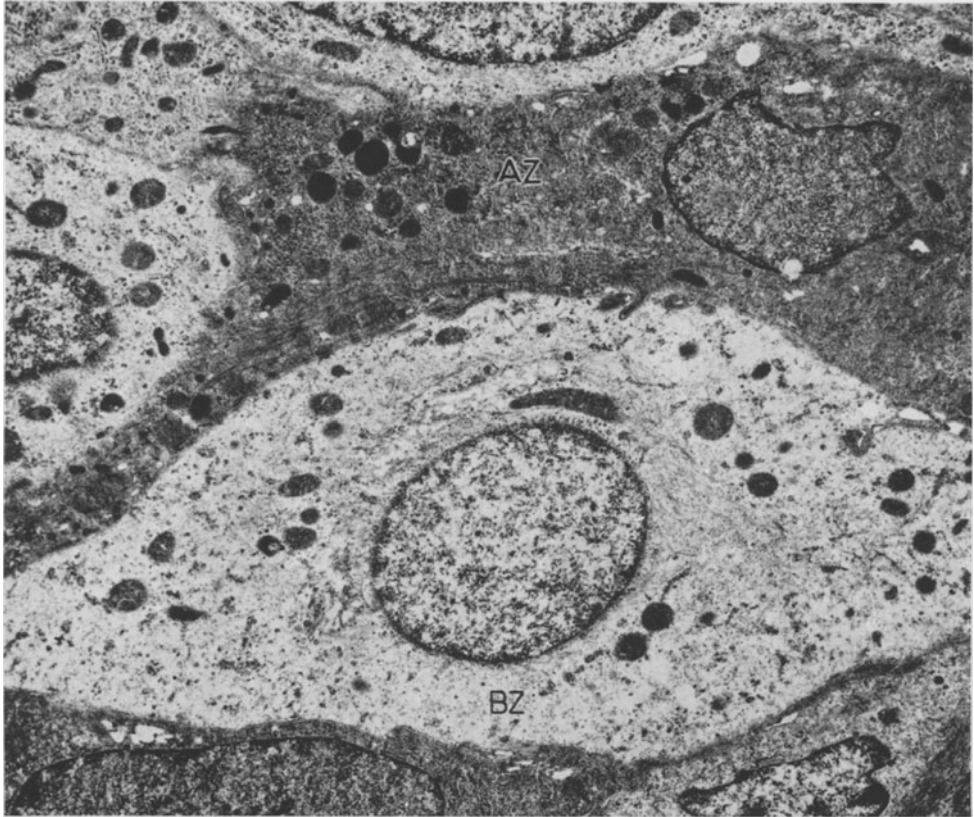


Fig. 7. Group of cells with dark A-cell (AZ): cytoplasm is rich in ribosomes and has bordering filaments. There are also clear B-cells (BZ): transparent cytoplasm, circumnuclear filaments, serrations with neighbouring cells. From a lobular carcinoma of a female. Record no. 1829/67: em. magnification 3,000; in the figure 9,600 ×

upon them like a shell upon the snail. When enlarged (lactation, congestion of secretion) the cell is flattened to a ribbon and is only recognizable by its parallel bundles of filaments. The first description of their electron microscopic structure in the female mammary gland was given by LANGER and HUHNS (1958); this was followed by the papers by TAKAHASHI (1958) and HAGUENAU (1959). It was possible to present the functional phases of myoepithelial cells by selective representation by impregnation with silver (HAMPERL, 1940; KUZMA, 1943; RICHARDSON, 1949/50; and LINZELL, 1952, 1955) and by determination of alkaline phosphatase with the azo-dyestuff method (BÄSSLER, SCHÄFER, and PAEK, 1967; BÄSSLER and BRETHFELD, 1968).

4. These cell types seen at the luminal surface of the cell groups are called *superficial cells*. They possess wide intercellular spaces, indicating a loosening of the cellular structure. They possess, moreover, an optically dark cytoplasm, rich in ribosomes, with wide fissures of the ergastoplasm. The mitochondria are usually swollen. The cytoplasmic changes are evidence of regressive alterations. These, together with their localization and the formation of inter-

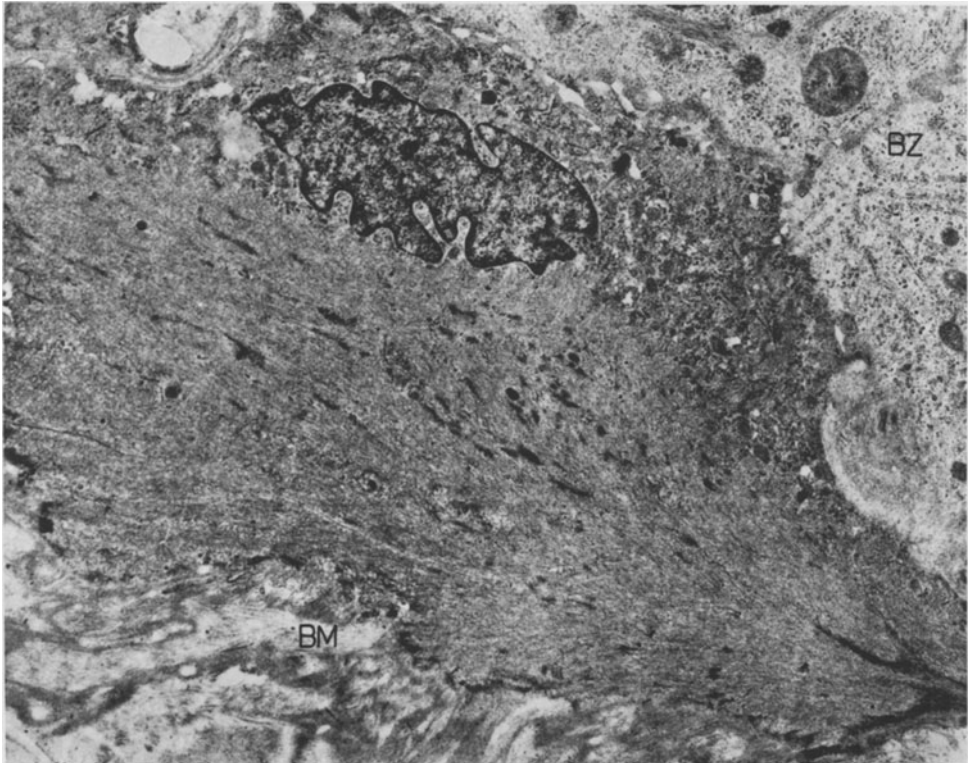


Fig. 8. Myoepithelial cell of the female mammary gland with dense fibrils, spotted densities, and hemidesmosomes. The nucleus is lobular, turned towards the epithelial cells and surrounded by organelles. Basal membrane structures (*BM*). At the margin a B-cell (*BZ*). Record no. 1832/67; em. magnification 3,000; in the figure 9,600 ×

cellular dehiscences, indicate a detachment from the cell group. Some groups of cells may remain in contact with the epithelial surface and may form epithelial buds or bridges, which protrude into the lumen. They are characteristic for gynaecomastia and are the typical outcome of experimental administration of oestrogen (Fig. 6). These superficial cells are therefore thought to be an indication of increased proliferation of the epithelium under the influence of hormones. The intensity of cell replacement is correlated with the degree of regressive changes in the cytoplasm of these cells.

Electron-microscopic findings of the human mammary gland may be compared from a cytomorphological point of view with the proliferations induced by hormones in animals. The mammary gland of the virgin rat

contains clear cells, rich in ribosomes, too. But after three days of treatment with oestrogen (5 γ /d) cells of differing basophilia appear in the loosened epithelium with intercellular gaps, which probably belong to one of the above categories. The cell types are not found in regular layers. The clear chief cells and the dark A-cells are found in equal numbers both in the base of the acinus and in the intermediary zone.

I believe that the development of these polymorphous cells, which differ in their ribosome content, is due to proliferation of the glandular epithelium, caused by hormones, especially by oestrogen.

IV. Effects on the Mammary Gland of Experimental Administration of Hormones

Ovarian Hormones

1. Oestrogen

Earlier investigations have shown that the mammary glands of different species react differently to oestrogen, when the hormone is administered in physiological doses. They may react either with proliferation of lactiferous tubules or with growth of tubules and simultaneous development of alveoli. FOLLEY in a comparative study (1956) demonstrated similar morphogenetic effects on certain species, when oestrogen was administered continuously (Table 2). Tissue response changes, however, when large doses are given continuously.

Table 2. *Effect of oestrogen on the mammary glands of different species*

1. Type: rat, mouse, rabbit, cat	→ growth of tubules, low-grade development of alveoli
2. Type: guinea pig, monkey, goat, cow	→ growth of tubules, intensive lobulo-alveolar development
3. Type: dog, ferret	→ low-grade growth of tubules

At first, differing statements about the hormone induced development of the mammary gland were made (LAQUEUR and DE JONGH, 1928; WEICHERT, BOYD, and COHEN, 1934). Out of this developed with increasing experimental experience a unitary concept of the mechanism of action. The essential parameters for the assessment of hormonal stimulation are the ages and weights of the animals, time of application, previous castration, hypophysectomy, and adrenalectomy (triple operation), single injections or depot effect, and duration of hormone supply.

In *newborn rats* oestrogen causes no glandular growth in the first and second weeks post partum, even when large doses (100 γ /day) are given. In the third week, however, the lactiferous tubules dilate and form buds, when

doses as small as $\frac{1}{10} \gamma/d$ are given (ASTWOOD, GESCHICKTER, and RAUSCH, 1937). — LEWIS and TURNER (1941) and AHRÉN (1959) discovered a morphological test for the minimum dose of oestrogen that would produce proliferation of the lactiferous tubules in castrated adult rats. The first named authors gave $0.25 \gamma-1 \gamma/d$ stilboestrol, the second named $1 \gamma/d$ as minimum dose. But even $10 \gamma/d$ induced limited growth of alveoli. TRENTIN and TURNER (1947) and CURTISS (1949) had obtained similar results when administering oestradiol propionate. REECE and LEATHEM (1945) had no success with the same drug.

The mammary glands of non-castrated rats grew intensively when oestradiol propionate was applied topically (LEONHARD and REECE, 1942). This was ineffectual if preceded by hypophysectomy (LEONHARD and REECE, 1942). — In rabbits and men unilateral topical inunction of follicular hormone (1,000 IU for 14—22 days) caused hyperplasia of the mammary gland with enlargement of the areola, and in men gynaecomastia (KUNERT, 1951).

Injections and implantations. The majority of experiments that had been carried out on castrated rats (WERNER, 1938; FAUVET, 1940; LEWIS and TURNER, 1941; WATTENWYL, 1949; TRENTIN and TURNER, 1947; CURTISS, 1949; LYONS, 1951; SMITH, 1955; AHRÉN, 1959; MOON and TURNER, 1960; McDONALD and REECE, 1962; reviews by MEITES, 1959a, and JACOBSON, 1961) showed that oestradiol dipropionate, oestradiol benzoate, and stilboestrol, in varying dosages and given by injection for up to 30 days, caused development of lactiferous tubules with formation of buds and development of alveoli of different widths. — Together with LIESER (1954) I demonstrated that the proliferation of the glandular system depended upon dose and duration of action: administration of $5 \gamma/d$ of oestradiol propionate (Progynon oleosum, Schering) resulted on the 20th and 50th day in increasing development of lactiferous ducts with dilatation, overgrowth of epithelium in the form of small papillomas, and lateral outgrowths. Large doses ($50 \gamma/day$) produced after 20 days multiple cysts, which enclosed a secretion containing both protein and fat. This oestrogenic effect was weak in non-castrated animals (HEROLD and EFFKEMANN, 1936), which instead showed proliferation and lobuloalveolar overgrowth, followed by an increase of circumcanalicular and intralobular connective tissue.

Even larger doses of oestrogen ($30-200 \gamma/d$) and the longer lasting treatment (20 to more than 300 days) caused the glandular tissue to react with proliferation and dilatation of the tubules, with formation of cysts and overgrowth of epithelium. The results of my own investigations are shown in Fig. 9. They demonstrate the regularity with which these effects occurred in castrated and non-castrated female rats. The studies of McEuen, Selye and Collip (1936), Astwood, Geschickter and Rausch (1937), Herold and Effkemann (1937), Astwood and Geschickter (1938), Biedermann (1938), Emge (1938), and Grumbrecht (1940) report the same results. — The relationships in time between the effect of oestrogen and morphogenesis were given

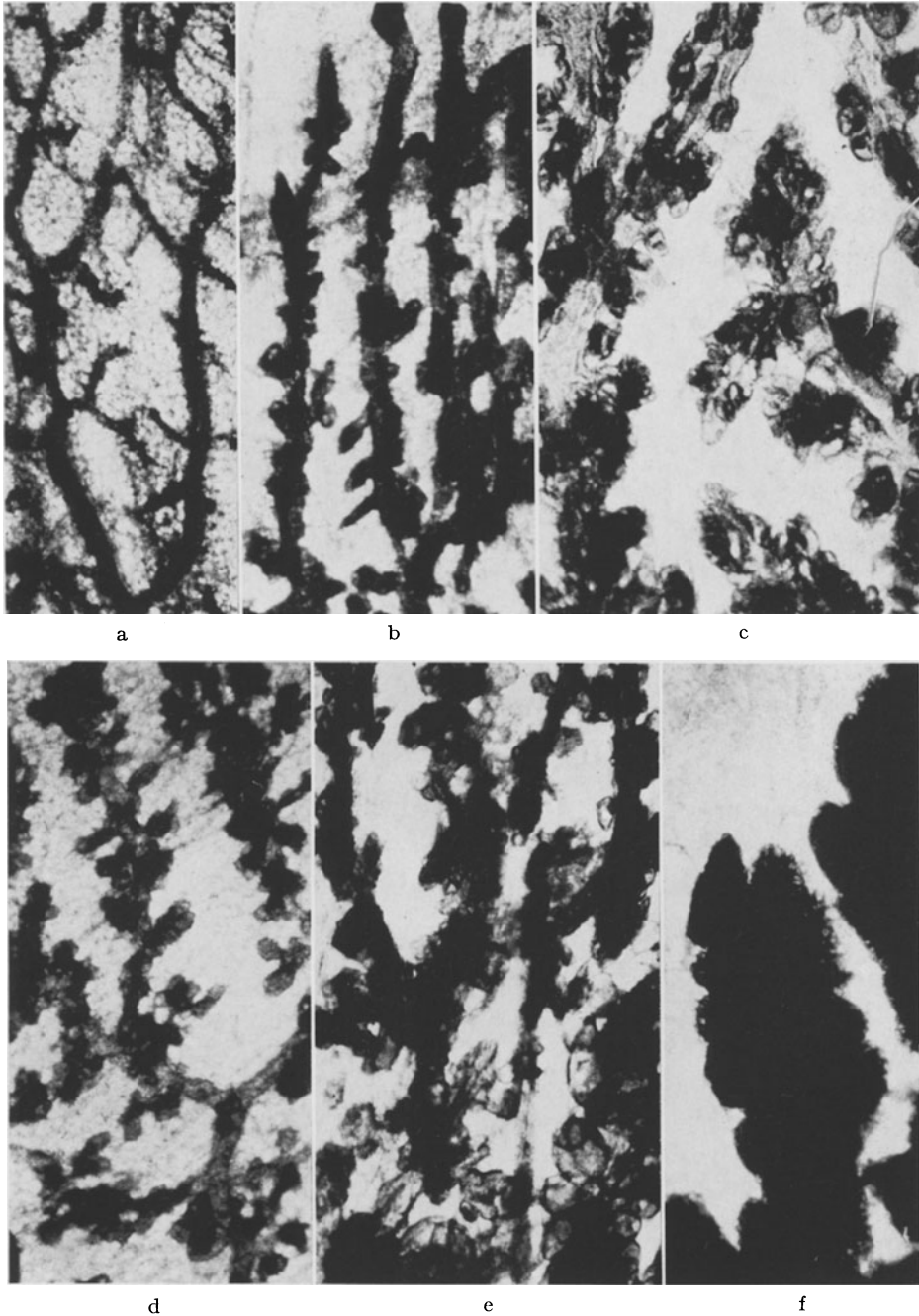


Fig. 9a—f. Morphology of the female mammary gland (rat) after treatment with hormones. a Castrated control animal. b Castrated, 5 γ /20 d Progynon: little dilatation of ducts, development of lateral arborization. c Castrated, 5 γ /50 d Progynon: considerable dilatation of ducts with increasingly developing lateral arborization. d Normal animal, 50 γ /20 d Progynon: regular branching of ducts and intensive arborization. A tendency to formation of lobuli. e Normal animal, 50 γ /50 d Progynon: general dilatation of ducts with dilated adventitious branchings. f Castrated, 10 mg/17 d Proluton: intensive and regular formation of lobuli. Formalin, alumcarmine, magnification 10 \times

by EISEN (1942) (implantation of oestradiol propionate, 1—20 mg for up to 27 months): the sequence was:

Proliferation of the tubular system	26th day
Secretion	40— 60th day
Dilatation of ducts	60— 90th day
Formation of cysts of up to 1 cm diameter	90—150th day
Fibrosing	150—180th day

The changes that occurred afterwards seemed to be comparable from a pathogenetic point of view with *fibro-cystic mastopathy*, by consensus of all authors, when treatment had been continued for a long time.

Influence on the oestrogenic activity by other drugs. Castration and adrenalectomy diminished the oestrogenic effect (TRENTIN and TURNER, 1947). After thyroidectomy the tubules developed energetically. When thyroxin and oestrogen were given after castration and thyroidectomy, the tubules grew and showed proliferation at the ends and sides (LEONARD and REECE, 1941). Combinations of the drugs and protamine-zinc-insulin (AHRÉN, 1959) given to castrated, hypophysectomized rats resulted in little proliferation only. — Oestrogen (0.1 mg) together with desoxycorticosterone acetate (5 mg/10 d) caused lobular development in castrated rats. Doubling of the dose was ineffective (SMITH and BRAVERMANN, 1953).

The same hormones are ineffective after hypophysectomy [LEONARD and REECE (1941)]. — LYONS, JOHNSON, COLE and LI (1955), LYONS LI and JOHNSON (1957), and LYONS, LI and JOHNSON (1958) carried out systematic studies to show that STH when given together with oestrogen had a definite proliferating effect on the lactiferous tubules after castration and hypophysectomy. When adrenalectomy was performed at the same time, oestrogen, STH, and desoxycorticosterone acetate caused proliferation of the lactiferous tubules, equal to that of normal 30—40 days old rats. After triple operation oestrogen, desoxycorticosterone acetate, STH, progesterone, prolactin, and prednisolone, all administered at the same time, caused uniform lobulo-alveolar differentiation of the gland. — Oestradiol in conjunction with either acetylcholine or epinephrine equally produced a lobular and alveolar glandular structure with secretion (MEITES, 1959).

The *mouse* reacts to oestrogen with growth of the lactiferous tubules, proliferation, and formation of alveoli. — In non-castrated animals dose-dependent proliferations are produced with alveolar differentiation that often is quite considerable (GARDNER, SMITH, and STRONG, 1935). Smaller doses of oestrogen (up to 10 mg/week) produce better development than large quantities (50 mg/week), which produce tumours after 220 days (GARDNER, 1941). TRENTIN and TURNER (1948) gave oestradiol benzoate for three days. This caused production of buds, but to only a sixth of the extent of that produced by the injection treatment, taking the development of the tubules as control standard. Growth of ducts, budding with secretion, and development of alveoli were evoked after castration (DAANE and LYONS, 1954). Castration and hypophysectomy prevented development (GARDNER, 1940; TRENTIN and

TURNER, 1948; FERGUSON and VISSCHER, 1953; FERGUSON, 1956). — Oestrogen and extract of the anterior lobe of the pituitary (in mouse units with mammo-genic action) gave different, though positive reactions in different strains of mice (MIXNER and TURNER, 1957), which indicated different sensitivities for oestrogen (MÜHLBROCK, 1948). Thyroxin given together with oestrogen and progesterone greatly increased the development of the mammary gland (MIXNER and TURNER, 1942c). According to MIXNER and TURNER (1942b) the effect of desoxycorticosterone acetate and oestrogen was about a third of that of progesterone. This combination when given to male hypophys-ectomized mice caused intensive proliferation (GARDNER, 1940), as did the combination of oestradiol propionate and purified prolactin (GARDNER and WHITE, 1941). — FERGUSON (1956) calculated that the rate of growth was normal with oestrogen, progesterone, prolactin, and STH, and that this was not increased by addition of ACTH and thyroxin.

FRAZIER and MU (1935) and LEWIS and TURNER (1941) had found in rabbits that oestrogen caused development of ducts with lobulation. According to SCHARF and LYONS (1941) five weekly injections of oestrogen (30—960 IU) caused gradual formation of ducts, of lobuli with secretion, and of cysts. LEWIS and TURNER (1942b) published their comparative investigations of the effect of percutaneous oestrogen on growth. According to JACOBSON (1954) the anterior lobe of the pituitary is prerequisite for the effect of ovarian hormones on the mammary gland. — According to recent observations by NORGREN (1966) the optimal dose lies between 2.5—5 mg/d when administered for 28—45 days. Larger quantities of oestrogen cause disorders of growth and of differentiation.

Second group: Guinea pigs, monkeys, cows, goats.

The reaction to oestrogen of the mammary tissues of these species is characterized by growth of the lactiferous tubules and lobulo-alveolar proliferation of the parenchyma.

This had been thought to be due solely to the effect of oestrogen (TURNER and GOMEZ, 1934; NELSON, 1937). LEWIS and TURNER (1942a) remarked on the dose dependency of lobulation; COWIE (1951) and SMITH and RICHTERICH (1958) pointed to the long duration of the experiments, which caused extensive formation of alveoli.

Local application had similar results (NELSON, 1941). HÖHN (1957) had shown recently that a progesterone that originates in the adrenal cortex was likely to be of importance for the lobular and alveolar development of the mammary glands of these species, because in castrated and adrenalectomized animals treatment with oestrogen caused proliferation of the tubuli only. BENSON, COWIE, COX and GOLDZWEIG (1957), too, had to use a combination of oestrogen and progesterone to obtain optimal development. — GARRETT and TALMAGE (1952) have reported on potentiation by relaxin.

Experimental studies of the mammary glands of *monkeys* by FOLLEY, GUTKELCH, and ZUCKERMAN (1939), GARDNER (1941), CHAMBERLAIN, GARDNER and ALLEN (1941; local application), GESCHICKTER and SPEERT (1941), and

SPEERT (1948) have provided evidence that oestrogens may produce a mammary structure that is completely ductular and lobuloalveolar. It is tempting to ascribe to this process in primates a special *significance for the pathology of the human mammary gland*. In long-term experiments, lasting seven years and seven months, with non-castrated and castrated rhesus monkeys (GESCHICKTER and HARTMAN, 1959) the lobular structure remained intact. Islets of pale epithelium, ectasias of the lobules, secretion, and fibroses, as regressive changes, began to appear. Although stimulation with oestrogens continued for years, no carcinomas were observed.

In ruminants the effect of oestrogen has been examined chiefly on the udder of *goats*.

MIXNER and TURNER (1943) had found that stilboestrol disturbed the development of the mammary gland, producing cysts and papillary proliferations of the epithelium. This became less obtrusive when progesterone was administered at the same time. COWIE, FOLLEY, MALPRESS, and RICHARDSEN (1952), BENSON, COWIE, COX, FLUX and FOLLEY, (1955) in comparative studies of the influence of both hormones in varying dosages have demonstrated abnormal folds and papillae of the alveolar epithelium when large doses of oestrogen were given, even when given together with progesterone. When smaller doses of oestrogen and progesterone were given the reactions became milder, so that the substance was considered essential for the development of the udder (BENSON, COWIE, FOLLEY and TINDAL, 1959).

The *udder of the cow* behaves similarly and for physiological development requires both oestrogens and progesterone (SYKES and WRENN, 1950, 1951; REINEKE, MEITES, CAIRY, and HUFFMAN, 1952; MEITES, 1960; FOLLEY, 1956). When oestrogen alone was given to cows, irregular structures of the alveoli were produced, which were characterized by small compressed and by ectatic-cystic areas.

The last group of species is distinguished by the fact that oestrogens have no or hardly any effect on the development of the mammary gland. *Ferrets and bitches* belong to this group. GARDNER (1941) had found in experiments with oestradiol benzoate that the lactiferous tubules of bitches grew only slightly or not at all even though the drug had been applied for up to 109 weeks.

The effect of *oestrogens* on the *mammary gland of male rats* was studied, so that the structural changes of gynaecomastia might be imitated. In my own experiments (BÄSSLER and SCHÄFER, 1968) the mammary glands of young male rats responded to Progynon (10 γ /d) after five and 10 days with growth of tubules and proliferation of the adventive-buds (Fig. 11). The same treatment applied to castrated animals resulted in intensive proliferation with production of small alveoli, a picture that simulated that of the female hormone-stimulated breast (Fig. 9). This development of the mammary gland is essentially determined by the antagonistic effect of testosterone. This statement may be used to clarify the pathogenesis of hormonally stimulated arborization in gynaecomastia, a process based on relative or absolute preponderance of oestrogens or of compounds with oestrogenic effect.

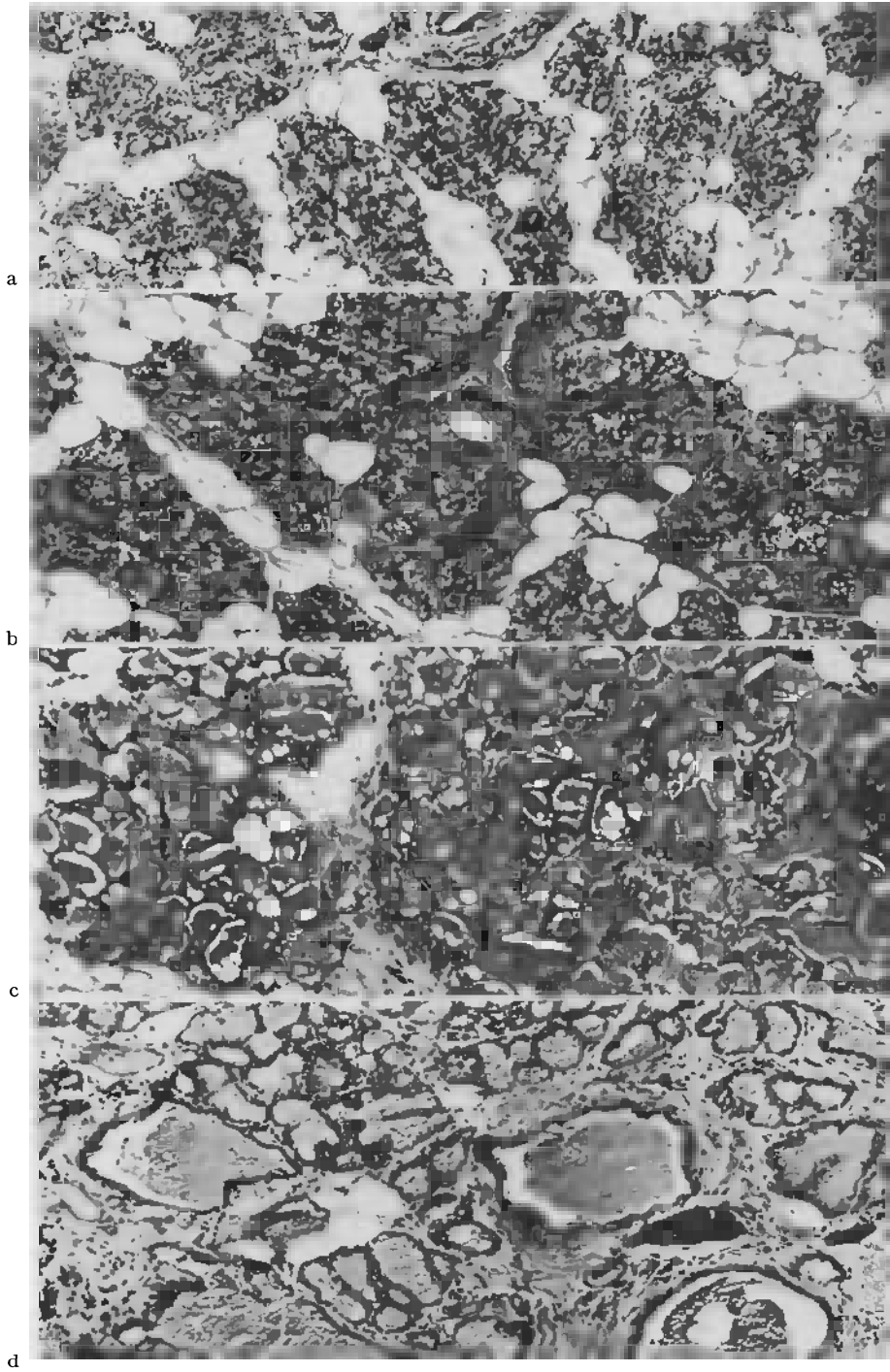


Fig. 10a—d. Effect of oestrogen, progesterone and prolactin on the mammary glands of castrated rats. a Lobular proliferation of the mammary gland with little secretion and formation of fat in the glandular epithelium after treatment with 5 γ Progynon and 5 mg Proluton for 15 days. b Greater lobular proliferation and secretion after 15 days

2. Progesterone

There is no doubt about the importance of corpus luteum hormone and follicular hormone for the normal development of the breast. There are, however, differences of opinion about the effects of progesterone. Dosage is the best criterion of morphogenetic action on the parenchyma of the mammary gland. The lower limits of effective dosage are 5 mg/d (10 days) for rats according to SELYE (1940a, b) and 2.4 mg/d (68 days) for guinea pigs by BENSON, COWIE, COX and GOLDZWEIG (1957). No doubt, these doses are far greater than the normal amounts which are used in combination with oestrogens, so as to obtain a steady lobulo-alveolar differentiation.

GARDNER (1940) gave to hypophysectomised *mice* 0.125—0.25 mg of corpus luteum hormone, but only weak growth of tubules resulted. TRENTIN and TURNER (1948) mentioned slight terminal budding and dilatation of tubules. Experiments by DAANE and LYONS (1954) were unsuccessful. MIXNER and TURNER (1942a), however, observed a lobulo-alveolar development after a dose of 6 mg in 57.7% of experimental animals. The same authors (1941a) obtained similar dose-dependent results with the orally active drug pregneninolone.

CORNER (1930), NELSON (1936), and SELYE, BROWNE and COLLIP (1936) denied that 4 mg/d of progesterone had any effect on the mammary gland of the *rat*. ASTWOOD, GESCHICKTER, and RAUSCH (1937), ASTWOOD and GESCHICKTER (1938), LYONS (1951), and SMITH (1955) on the basis of their experimental results also doubted that progesterone had an isolated effect. SELYE (1940a, b), GESCHICKTER and BYRNES (1942), CHAMORRO (1944), and AHRÉN (1959a) by greatly increasing the usual dose were able to induce a development of the mammary gland with lobulation, that simulated the picture of late pregnancy. SELYE (1940) underscored the compact structure of the lobuli and went so far as to call progesterone *the* steroid hormone with the best production of acini. CURTISS (1949) alone was unable to confirm SELYE'S finding in a similar experimental arrangement and pointed out the differences between isolated animals and those kept in groups. SMITHCORS and LEONARD (1943) obtained growth impulses of the mammary glands in castrated and hypophysectomized rats with 10—30 mg/d, given for 10 days, provided the hormone injections were given immediately after operation (LEONARD, 1943).

Together with LIESER (1964) I had found in juvenile castrated female rats that the tubular structure of the breast had remained unchanged after 20 days of treatment with 1 mg/d progesterone. Only the circumtubular connective tissue had increased. Large doses (10 mg/d) produced lobuli in dense stratification, which simulated the picture of late pregnancy (Fig. 9f).

of treatment with 5 γ Progynon, 5 mg Proluton, and finally treatment with prolactin 2 mg/d for three days. c Considerable secretion with development of dilated alveoli. Same pretreatment, followed by six days of 2 mg/d prolactin. d Lobules with diminished secretion and retention, cysts and dilated excretory ducts with circumcanalicular fibrosis.

Same pretreatment, followed by 12 days of 2 mg/d prolactin

In *rabbits* (NORGREN, 1966) and *guinea pigs* small doses of progesterone were also ineffective (SMITH and RICHTERICH, 1958). COWIE (1951) compared the dose and proliferation effects and, like BENSON, COWIE, COX, and GOLD-ZWEIG (1957), obtained an effect on the growth of the tubular system only with 2.4 mg/d, given for 68 days.

3. Combined Action of Oestrogen and Progesterone

The results of these investigations indicate that neither oestrogen nor progesterone alone will produce a condition of uniform development and secretion of the mammary gland. Obviously, suitable combinations of the drugs might be tested to ascertain the optimal quantities of each hormone that would be appropriate normally for each animal species (Figs. 9, 10, 12a, b).

MIXNER and TURNER (1941 a, 1942 a, b) reported the quantitative relationships for the optimal development of the mammary gland of the *mouse* as being 1 mg progesterone and 40—1,200 IU oestrogen. High environmental temperatures (35°C) and thyroidectomy reduced the activities of the drugs. Experiments on non-castrated animals (TRENTIN and TURNER, 1948) and castrated mice (MIXNER and TURNER, 1957) also indicated species-dependent reactions. The findings of DAANE and LYONS (1954) and ANDERSON, BROOK-RESON, and TURNER (1961) underscore the syntropic lobulo-alveolar reaction, which was also observed in hypophysectomized male animals (GARDNER, 1940). MIXNER and TURNER (1943) gave a ratio of 1:75—250 oestrogen to progesterone as lobuloalveolar growth factor (see Table 3).

The mammary gland of the *rat* behaves similarly (NELSON, 1936; ASTWOOD and GESCHICKTER, 1938; MIXNER and TURNER, 1941 b). FAUVET (1940) in view of WERNER'S (1940) work took the view that it was possible to produce a functioning mammary gland with oestrogen alone, but that this development took too stormy a course in experimental work. Only synchronous protracted influence made organic development possible. Subsequent studies by CURTISS (1949), LYONS (1951) and by FOLLEY (1940, 1947, 1952, 1956) confirmed that in rats the complete and proper development of the mammary gland was possible only by combined treatment. SMITH (1955), BENSON, COWIE, FOLLEY, and TINDAL (1959), — who pointed to the uniformity of growth — AHRÉN (1959a), LINZELL (1959) and MEITES (1959a) confirmed these findings. MOON, GRIFFITH and TURNER (1959) pointed to age, interval between injections, and duration as special factors in the assessment of these experiments. McDONALD and REECE (1962), AHRÉN and JACOBSON (1956), and AHRÉN and ETIENNE (1958) discussed questions of dosage. — KIRKHAM and TURNER (1954), SMITH and RICHTERICH (1959) used the ratio of 3—5 mg progesterone to 1.0 mg oestradiol benzoate and observed at optimal differentiation that enzyme and DNA-values rose only little even when administration of the hormones was continued. In the state of maximal differentiation there is thus a rest phase of proliferation.

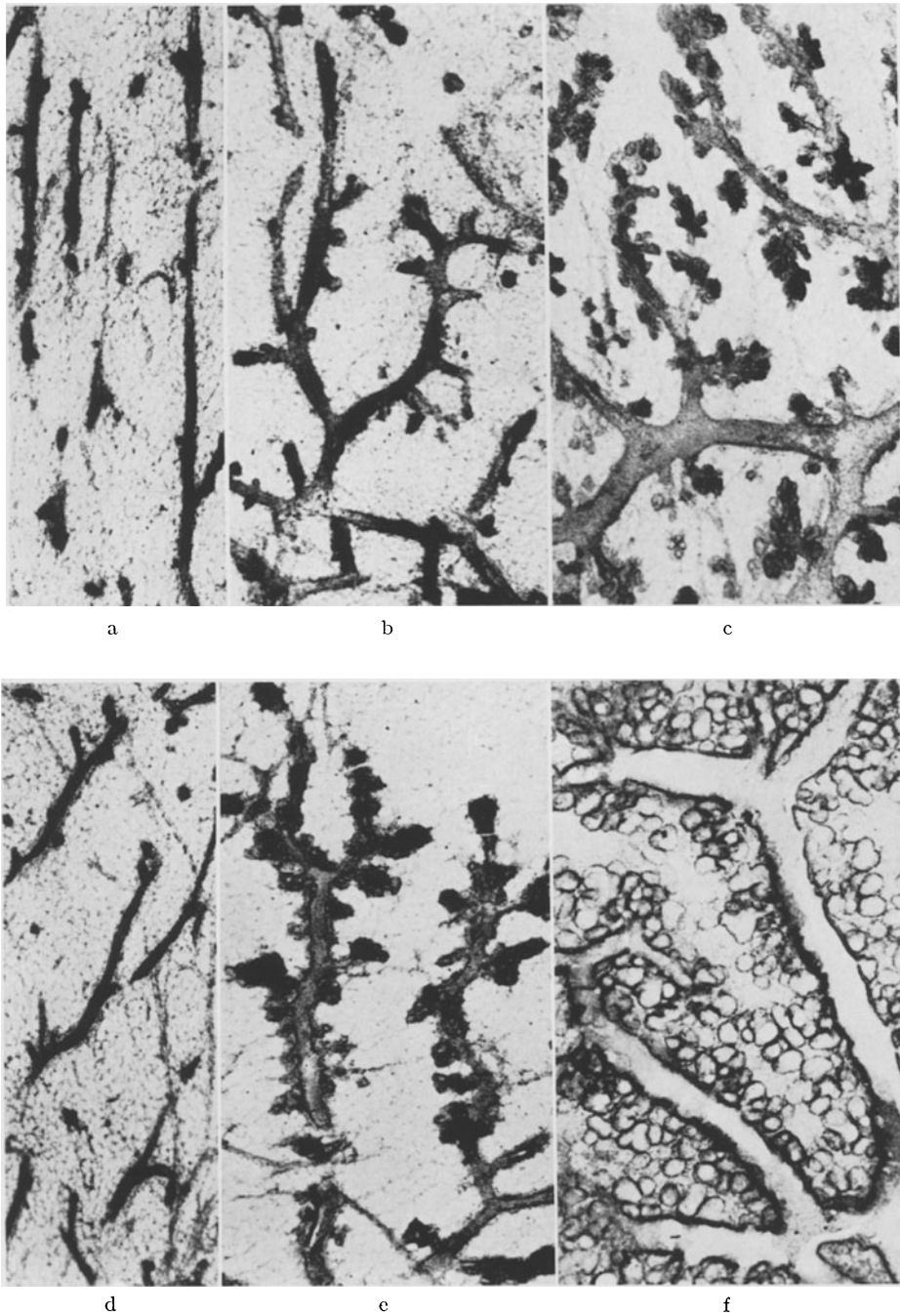


Fig. 11 a—f. Morphology of the male mammary gland (rat) after treatment with hormones. a Control animal, castrated. b 10 μ /5 d Progynon: dilatation of duct system and formation of broad lateral branches, small lobules. c 10 μ /10 d Progynon: strong lobular development with dilated alveoli, milk ducts, and secretion. d Control animal, not castrated. e 10 μ /5 d Progynon: proliferation of the tubular system and development of small lateral branches. f 10 μ /10 d Progynon: lobular and tubular development of glands with dilatation of lactiferous ducts. — Formalin, alumcarmine, magnification 10 \times

Hypophysectomized animals reacted to the combination of hormones only if injection treatment began immediately after operation. Additional desoxycorticosterone had no noticeable effect (SMITHCORS and LEONARD, 1943). — LYONS (1951, 1953) observed after hypophysectomy only insignificant formation of buds.

All dosage ratios are ineffective in castrated and hypophysectomized rats (AHRÉN and JACOBSON, 1956; AHRÉN and ETIENNE, 1958; AHRÉN, 1959). — When 2 mg oestradiol benzoate and 6 mg progesterone were given to castrated, thyroidectomized, and parathyroidectomized rats, the mammary gland proliferated and DNA increased after 19 days (v. BERSWORDT-WALLRABE and TURNER, 1960).

COWIE (1951) found in systematic studies that the ratio for *guinea pigs* was 50—100 mg oestrogen and 600—2,400 mg progesterone. BENSON, COWIE, COX and GOLDZWEIG (1957) a few years later found that the gland developed maximally when a ratio of 1:20—100 was given. They noted that the quantities of the drugs as well as the ratio were of importance, in that amounts of less than 0.1 mg oestrogen caused formation of cysts.

SCHARF and LYONS (1941), LYONS and MCGINTY (1941), and YAMAMOTO and TURNER (1956) found similar results in *rabbits*. The proliferated glandular fields could only be distinguished from those during pregnancy by incomplete lobuli in the periphery. NORGRÉN (1966) obtained optimal lobular differentiation by administering graduated doses of oestrogen (5—20 mg/d) and progesterone (1—5 mg) for 28 days. Progesterone alone was ineffective.

COWIE, FOLLEY, MALPRESS and RICHARDSON (1952) found in castrated *goats* that combinations of hexoestrol and progesterone resulted in uniform development and secretion, provided the dose of oestrogen (0.25 mg/d) remained small. An increase to 1 mg/d produced cysts and epithelial proliferation. BENSON, COWIE, COX, FLUX and FOLLEY (1965) obtained similar results in castrated virgin goats, and BENSON, COWIE, COX, FOLLEY, and HOSKING (1965) obtained similar results after daily injections of oily solutions and of depot preparations. The oily solutions that were administered daily proved more effective than crystalline depot suspensions. After complete hypophysectomy the drugs were ineffective. After castration and hypophysectomy hexoestrol, progesterone, prolactin, and STH induced lobulo-alveolar development (COWIE, TINDAL, and YOKOYAMA, 1966). SYKES and WRENN (1951), HANCOCK, BRUMBY, and TURNER (1954), and TURNER, YAMAMOTO, and RUPPERT (1956) studied the udders of *cows* and showed the importance of progesterone for the uniform development of a proficient udder.

The empirically obtained *optimal ratios for the lobulo-alveolar development of the mammary gland* are presented in Table 3.

Comparative studies by SOEMARWOTO and BERN (1958) of the *vascularization of the mammary gland under the influence of sex hormones* in C₃H/He Crgl mice have shown impressive differences. Vascularization during the genital cycle did not change as shown by injections of Indian ink and by making thick sections translucent. It increased during pregnancy and lactation, however,

Table 3

Species	Ratio of oestrogen: progesterone	Authors
Rat	1:1,000—5,000	KIRKHAM and TURNER (1954)
	1:3,000—5,000	SMITH (1955)
	1:4,000—5,000	MCDONALD and REECE (1962)
Mouse	1:75—250	MIXNER and TURNER (1943)
Rabbit	1:10—40	LYONS and MCGINTY (1941), SCHARF and LYONS (1941)
	1:67	YAMAMOTO and TURNER (1956)
Guinea Pig	1:20—100	BENSON, COWIE, COX, GOLDZWEIG (1957)
Goat	1:140	BENSON, COWIE, COX, FLUX and FOLLEY (1955)

and under the influence of oestrogen and progesterone capillary plexus formed around tubules and adventitious buds. This indicates that there is a correlation between hormonal action, vascularization, and development of the gland, and that this correlation may be cancelled by hypophysectomy and ovariectomy.

4. Histochemistry of Connective Tissue During Hormone Action

After puberty in man the mesenchymal portions of the mammary gland differentiate into loose intralobular connective tissue, called "mantle tissue" by BERKA (1914). This is particularly concerned with the hormonally induced changes of the glandular apparatus. The coarsely fibred, collagenous connective tissue surrounds tubules and lobules and acts as supportive tissue in anchoring the body of the gland in the Fascia pectoralis and in the corium (GRUBER, 1921; DIECKMANN, 1925; SCHULTZ, 1933; DABELOW, 1957). In disorders of the mammary gland multiple histopathological changes of structure occur in connective tissue, which exhibit as secretion of fluid, oedematous-mucoid swellings of this stroma, and hyalinisation. The depositions of fluid observed in fibrocystic mastopathy and carcinoma were called "oedema lakes" by RATZENHOFER (1951), RATZENHOFER and SCHAUENSTEIN (1952a, b). They contain 1—6 g-% protein, mainly albumin, thought to derive from permeable blood-vessels and presenting precursors of the fibrillar and hyaline collagen. This permanent invasion of fluid with abnormal proteins is of great importance in mastopathy (RATZENHOFER, 1951).

Histochemical studies have been restricted to the recognition of mucopolysaccharides: according to KURU (1909) and SYLVEN (1938) the stroma is not metachromatic. In contrast, investigations by CONSOLANDI (1947), OLIVI and BARBIERI (1952), IHNEN and PEREZ-TAMAYO (1953) have shown low-grade positive reactions. VERONESI and CANDIANI (1955) have described PAS-positive deposits in the lactiferous ducts, metachromatic material and mucicarmine staining components. DEMPSEY, BUNTING and WISLOCKI (1947) and BUNTING (1950) had found metachromasia in mantle tissue that was at

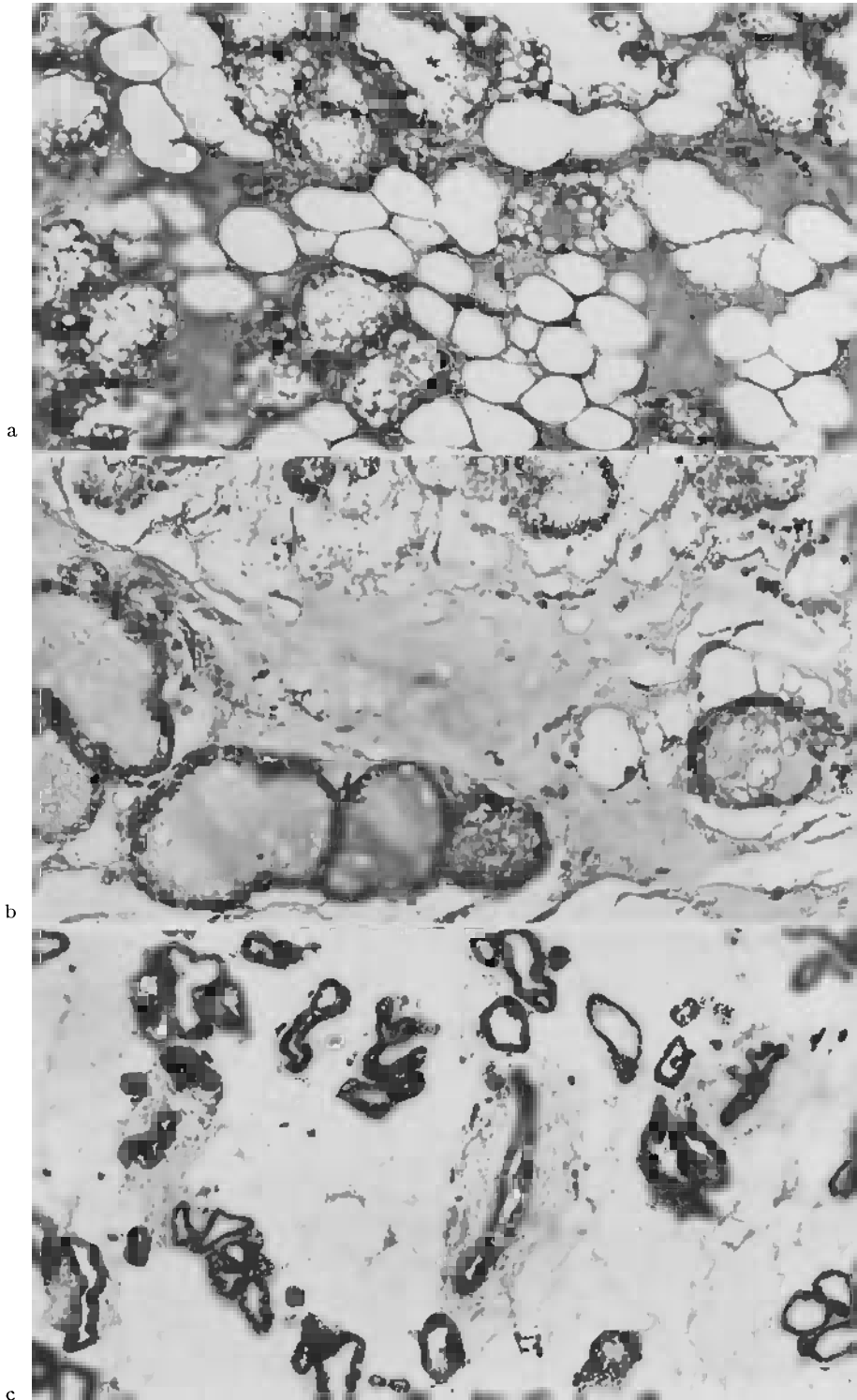


Fig. 12a—c

least partially stable for testicular hyaluronidase. Systematic studies by OZZELLO and SPEER (1958) showed positive PAS- und Hale-reactions with metachromasia to toluidine blue in the intralobular and circumductal connective tissue. The intensity of the reactions depended upon the menstrual cycle in so far as the time of strong oestrogen activity was related to a rise of acid mucopolysaccharides. Correspondingly, this effect was reduced in the menopause.

New histochemical investigations by LEUSCHNER (1969) demonstrates deposits of metachromatic and periodine reactive substances in solid-scirrhous carcinoma of the mammary gland indicating growth activity.

SCHULZE (1968) had tested histochemically the relationships between mucopolysaccharide content and sex hormone. She had found that castrated rats showed a rise of acid muco-polysaccharides after treatment with oestrogen. CHAIN and DUTHIE (1940), DURAN-REYNALS, BUNTING, and VAN WAGENEN (1950), VITRY (1953), OZZELLO and SPEERT (1958) reported similar observations. Progesterone, on the other hand, inhibited the mesenchymal action of oestrogen (ASBOE-HANSEN, 1958, 1959). I was able to confirm this in the animals that had not been castrated and had not received additional progesterone. Animals that had been pretreated for 10—20 days with hormones started to secrete profusely, and developed distension of the glandular alveoli, cysts, and congestion of the secretion. As treatment proceeded, homogenous and finely granulated deposits occurred in the intra- and interlobular connective tissue, which after acetylation and saponification reacted positively, but to varying degrees, to PAS and Hale (Fig. 12a, b). In view of the pathology of the human mammary gland in hormonally induced dysplasias and in involution after lactation it may thus be assumed that these deposits are present in the preformed mesenchyma and, like vascular albumins (RATZENHOFER and SCHAUENSTEIN, 1952), are of importance for the fibrosing of glands (BÄSSLER, SCHULZE and SCHRIEVER, 1970).

The increase of *mast cells*, which settle in the circumductular and lobular mesenchyma when the connective tissue develops further on stimulation by hormones is thus explicable (Fig. 12c). The mast cells, first demonstrated and counted in the mammary gland of man and in dysplasias by HIGUCHI, (1930) are formed in the "mantle tissue", i.e. the cytogenous stroma, and are supposed to increase in the transitional area between carcinomatous and healthy tissue, and in lactation and mastopathy. They are said to be scarce

Fig. 12a—c. Mucopolysaccharide and mast cell presentation in the stroma of mammary gland after hormonal stimulation. a Castrated rat after treatment with Progynon (5 γ) and Proluton (1 mg) for 10 days. Lobular proliferation of gland and intensive secretion. Homogenous dense deposits in the circumlobular connective and fat tissue. Saponification and PAS, magnification 70 \times . b Normal animal after the same treatment. The terminal sectors of the gland are filled with secretion, in the connective and fat tissue homogenous, cloudy deposits are seen. Acetylation and PAS, magnification 230 \times . c Castrated rat after treatment with 5 γ /50 d oestrogen. Tubular proliferation and dilated ducts. Staining with toluidine-blue, mast cells represented in peritubular stroma (black dots). —

Magnification 90 \times

in fibroadenoma and fibrosis and are unsystematically arranged in carcinoma (LEUSCHNER, 1969).

5. Histochemical Enzyme Model

Enzymes have been demonstrated so far mainly in tissue homogenates. The assay has been related to problems of the synthetic activity of the mammary gland during pregnancy, lactation, and involution (HANSEN and CARLSON, 1961; MUNFORD, 1964). Histotopochemical studies have been comparatively neglected and have been limited to demonstrations of alkaline phosphatase activity (DEMPSEY, BUNTING and WISLOCKI, 1947; VERNE, 1951; PERRINI, 1952; SILVER, 1954; HOLMES, 1956).

In recent histochemical enzymatic studies of the infantile, juvenile, and proliferating mammary glands under the influence of sex hormones topical enzyme models have been demonstrated, which depend upon the duration of action (PAEK, 1967; LANI, 1967; BÄSSLER and PAEK, 1968): *alkaline* and *acid phosphatase* and also *glucose-6-phosphatase* are localized in the base of the epithelial cells, especially of the myoepithelium, and form ribbon-shaped reaction products in infantile and juvenile animals and after hormone stimulation (Figs. 13 a, b). It is possible by means of azodye selectively to stain the myoepithelial cells. The behaviour of this cell system may thus be studied in the growing gland and during phases of physiological functioning (Fig. 13 b) (BÄSSLER and BRETHFELD, 1968). Irrespective of the galactokinetic importance of the basket cells the localization of the phosphatases in the basal boundary zone towards the vascular mesenchyme points to their importance for the uptake of substances from the blood stream. Electronmicroscopic histotopochemical findings have shown selective visualisation in the cell membranes (Fig. 15 a), with basal folds also showing strong positive reactions (Fig. 15 b). GIRARDIE and WOLF (1967) had thought that this localization indicated active transport of fluid by pinocytosis. — *Glucose-6-phosphatase* biochemically liberates glucose in the cell and is the primary source of fatty acid synthesis in nonruminants (FOLLEY and McNAUGHT, 1961). The localization shown in Fig. 13 a thus marks the site where phosphate groups are split off and where glucose enters the base of the epithelial cells.

An increase of acid hydrolytic enzyme activity, specially *acid phosphatase*, during the period of involution is revealed by electron microscopy, histo- and biochemically (HELMINEN, ERICSSON and ORRENIUS, 1968; BRANDES, ANTON and BARNARD, 1969; ZARZYCKI, PERYT, KLUBINSKA, HJAC and ZAK, 1969). The results indicate the activity of lysosomes in areas of focal cytoplasmic degradation in the glandular and macrophage-like cells.

Adenosine triphosphatase is localized exclusively in the mesenchymal parts of the mammary gland, especially in blood-vessels, nerves, and lymph nodes. It shows differences of reactions only when there is congestion of milk with increased fluid outflow. MEIER-RUGE (1966) and HOLZNER and KAUFMANN (1965) have described in carcinoma of the breast rises of intensity of ATP-ase, whereby a kind of negative picture of the tumour tissue is created.

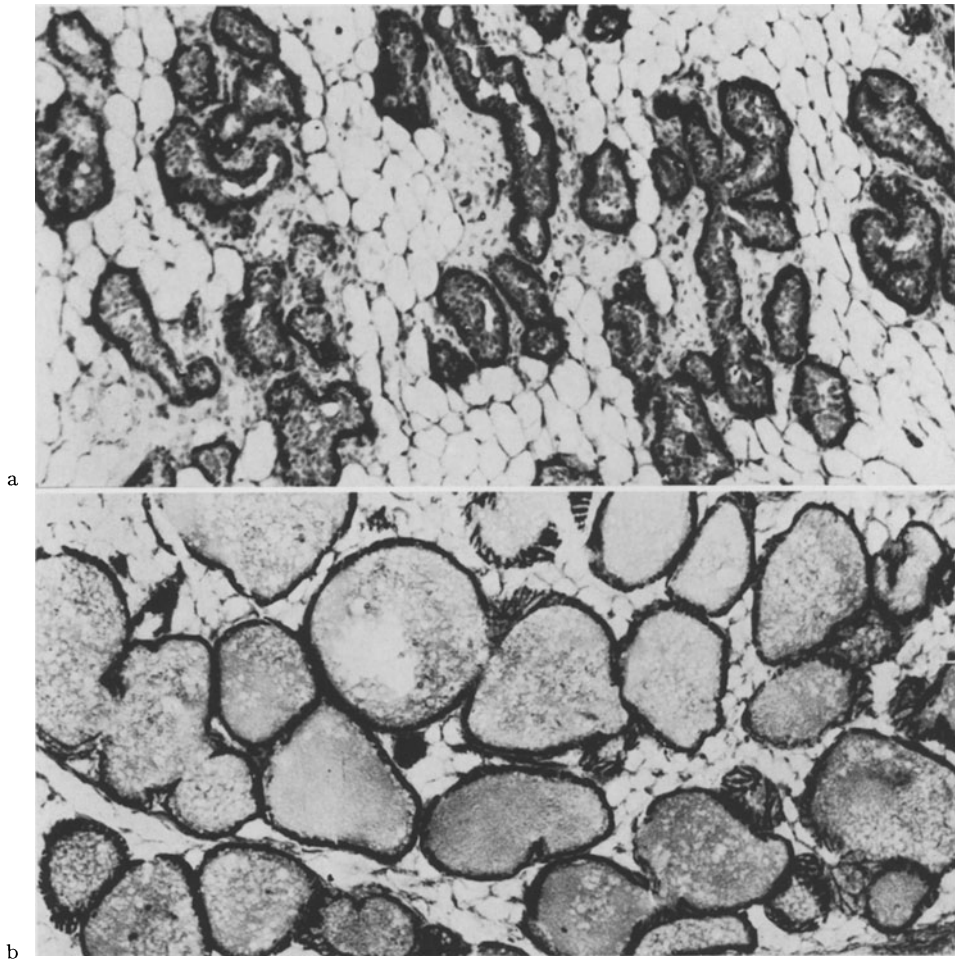


Fig. 13. a Demonstration of glucose-6-phosphatase in the base of proliferating tubules after treatment of a castrated rat with oestrogen for five days (magnification $90\times$). b Alkaline phosphatase (azodye method) in the base, especially in the myoepithelium of dilated and secreting alveoli. Treatment of a castrated rat with oestrogen and progesterone ($1:1,000$) for 10 days. Magnification $90\times$

5-nucleotidase possesses only insignificant activity in the epithelial cells and rises only little under the influence of hormones. The same applies to *succinodehydrogenase* and *glucose-6-phosphate-dehydrogenase*, the key enzyme for the pentose-phosphate cycle (GLOCK and MCLEAN, 1954).

When the mammary glands of castrated animals were stimulated with oestrogen and progesterone the intensity of the enzymatic reaction products rose, remained high up to the fifth day, and then levelled out. Continued administration of hormone caused no further change. In other words, on the fifth day the hormonally induced cell metabolism had reached a constant level (Fig. 14a, b). *The effects of oestrogen dominated*, and were not greatly increased by progesterone and prolactin. — When the mammary gland had

been pretreated and had proliferated, and prolactin was injected for several days, retention of secretion in the alveoli and epithelial caused a reduction of enzyme activity.

The development of the mammary gland during pregnancy and lactation is related to a general increase of enzyme activity. Involution is related to a reduction of activity, as is to be expected. The metabolic and catabolic pro-

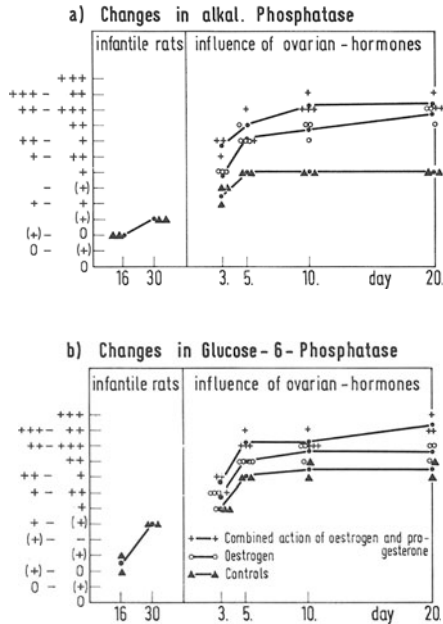


Fig. 14. The histochemical changes of enzyme activity under the influence of oestrogen and progesterone (PAEK, 1967)

cesses in glandular and fat tissue are marked by great activity of non-specific esterases (BÄSSLER and BRETHFELD, 1968).

FISCHER and SCHAEFER (1967) and SCHAEFER and FISCHER (1968) observed oestrogen-dependent activity of alkaline phosphatase in subcutaneous fibroblasts. They had also found that phosphatase activity was influenced by sex, castration, time and dosage of hormone treatment. These observations seem to point to neosynthesis of this enzyme, which is stimulated by oestrogen and directed by messenger RNA.

6. Electron-Microscopic Morphology of the Hormonally Stimulated Mammary Gland

Under *normal conditions* the glandular cells of young animals are characterized by their cubic shape, which becomes prismatic when they are in superficial position. The cytoplasm is relatively poor in differentiation products and surrounds an ordinary oval nucleus. The epithelial surface may protrude hemispherically or sometimes tongue-shaped, into the lumen. It possesses

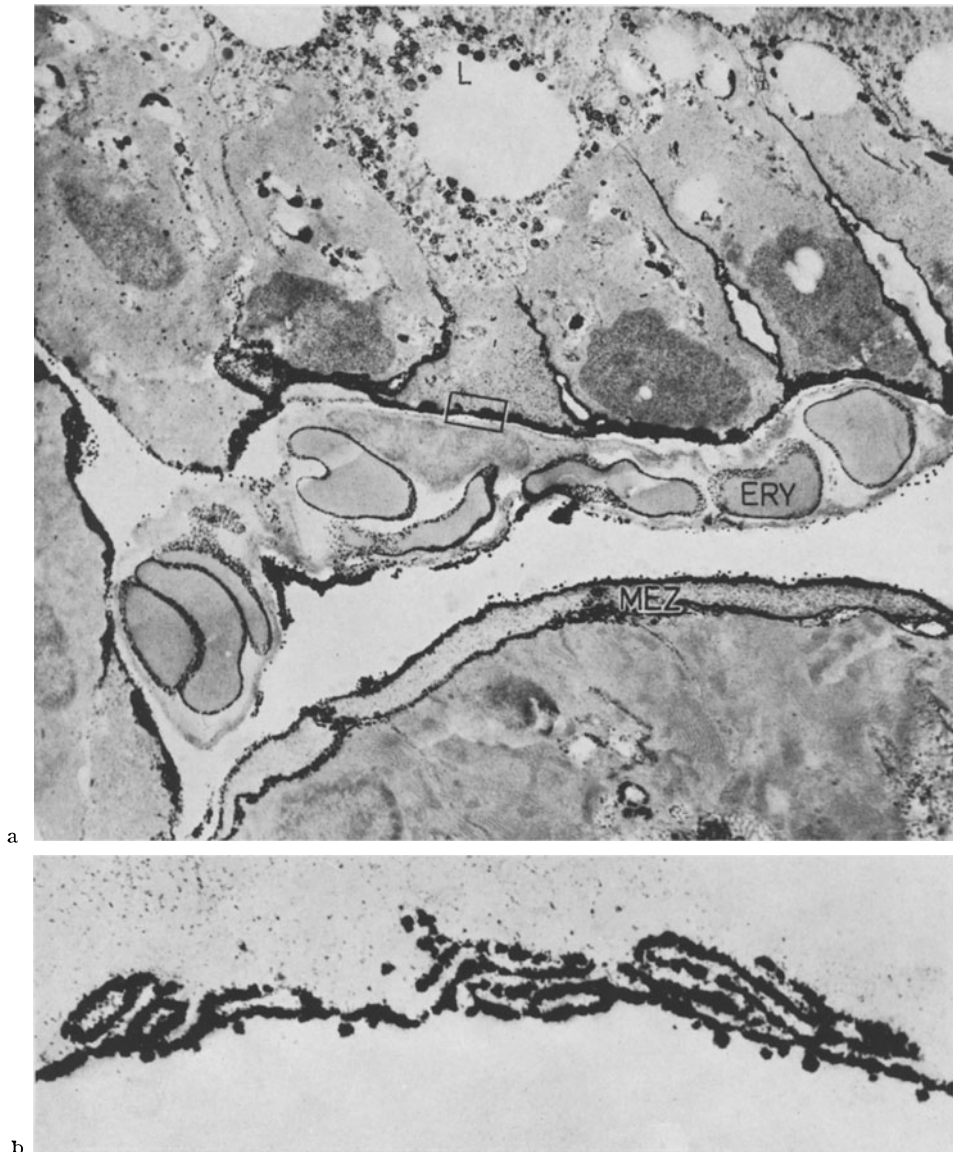


Fig. 15. a Electronmicroscopic representation of the siting of alkaline phosphatase (azo-method) in the lactating mammary gland. The reaction products are shown as black deposits in the cell membranes, myoepithelium (*MEZ*), partly in the lumen of the gland (*L*) and in the membrane of erythrocytes (*ERY*). Record no. 1299/68; em. magnification 2,400; in the fig. 5,525 \times . b Enlargement of sector of the basal membrane of a glandular cell with basal folds, which are characterized by reaction products of the azodye method. Record no. 1292/68; em. magnification 13,500; in the figure 31,050 \times

microvilli of various sizes. The large microvilli frequently become detached and together with parts of detached cells form a detritus that partially fills the small lumina (Fig. 16). At the apical end of these gaps are found basal folds, indentations, desmosomes of the cell membranes, and also thickened

ridges, which serve to hold the cells together against pressure or tension forces, arising from secretion or retention, which may deform the groups of cells. During the resting state of the epithelial cells the energy carriers for synthetic activity, the mitochondria, are small and sparsely distributed in the ribosome-rich cytoplasm. The Golgi field, which consists of small gaps and small vesicles and is optically empty, lies beside the nucleus. Near the

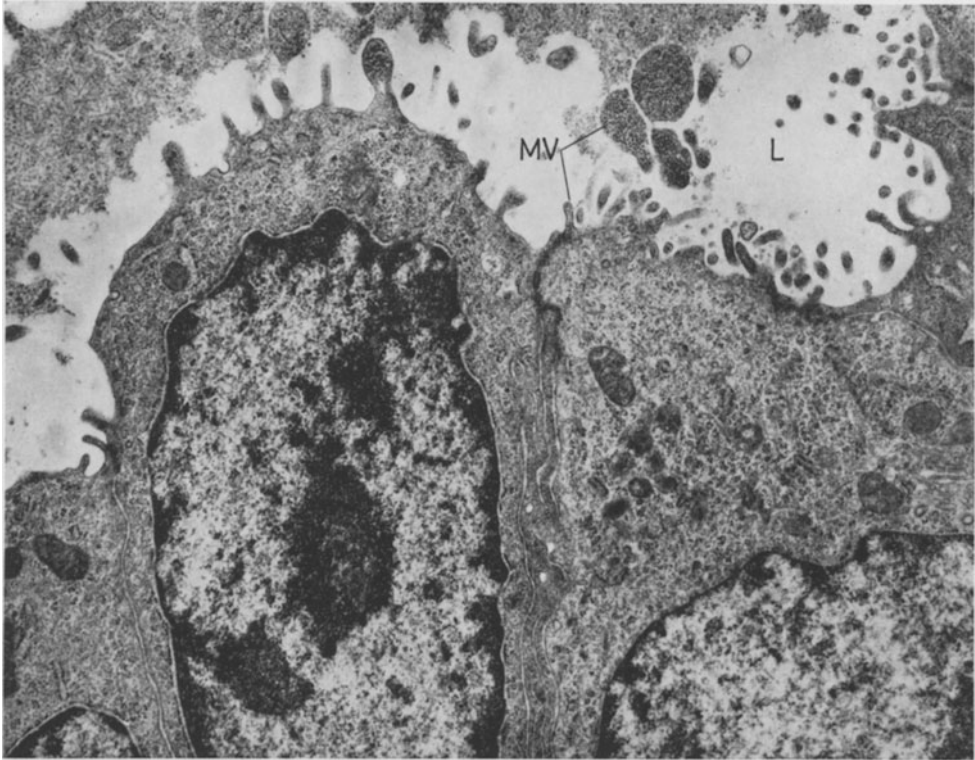


Fig. 16. Glandular epithelium of the mammary gland of a juvenile rat with regular cytoplasmic structure. On the surface microvilli (*MV*) of varying size, some in the stage of constriction. In the lumen (*L*) detritus and remnants of secretion. In the cell plasma ribosomes and a few mitochondria. Record no. 1384/68; em. magnification 7,500; in the figure 18,000

epithelial base small fat vacuoles, occasionally also short pairs of lamellae of the endoplasmic reticulum may occur.

The action of *oestrogen* may be recognized morphologically after two days by proliferation of the epithelium with intercellular gaps, and by desquamation of superficial cells. The content of ribosomes in the cytoplasm increases; an ergastoplasm develops with lamella that are widely set apart; the nuclei are dark and have a large nucleolus. — After treatment with *oestrogen* for several days epithelial proliferations goes together with increasing differentiation of the cytoplasm, which shows large swollen mitochondria of the matrix and crista type (THOENES, 1964). The cytoplasm becomes more transparent and contains

numerous fat vacuoles, which are surrounded by mitochondria or by ergastoplasmic lamellae (Fig. 17). Fat synthesis is at first localized in the base of the cell. This is also the site of lysosomes, phagolysosomes, siderosomes, and vesicular bodies, which appear as results of hormonal action. After treatment

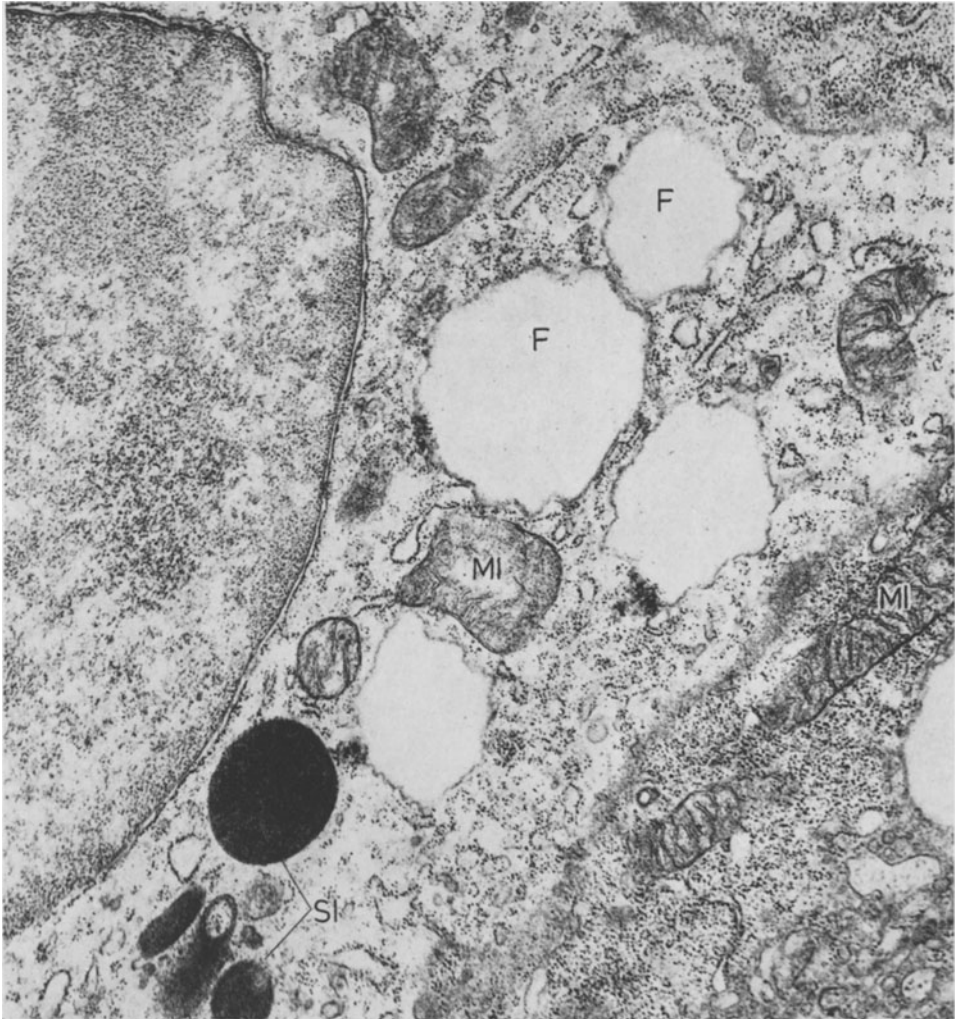


Fig. 17. Sector of cytoplasm and nucleus of a glandular epithelial cell of the mammary gland after castration and treatment with oestrogen for 10 days. In the perikaryon several fat droplets (*F*), large mitochondria (*MI*) and siderosomes (*SI*). Record no. 892/66, em. magnification 8,000; in the figure 26,400

for 20 days fat synthesis is nearly ubiquitous. Fat issues in the form of small droplets into the enlarging lumen of the gland. These droplets consist of small round fat particles and larger confluent particles (Fig. 18). The Golgi field also increases in size, but always remains free from secretion products. The casein synthesis characteristic for lactogenesis does not occur after experimental treatment with oestrogen and progesterone.

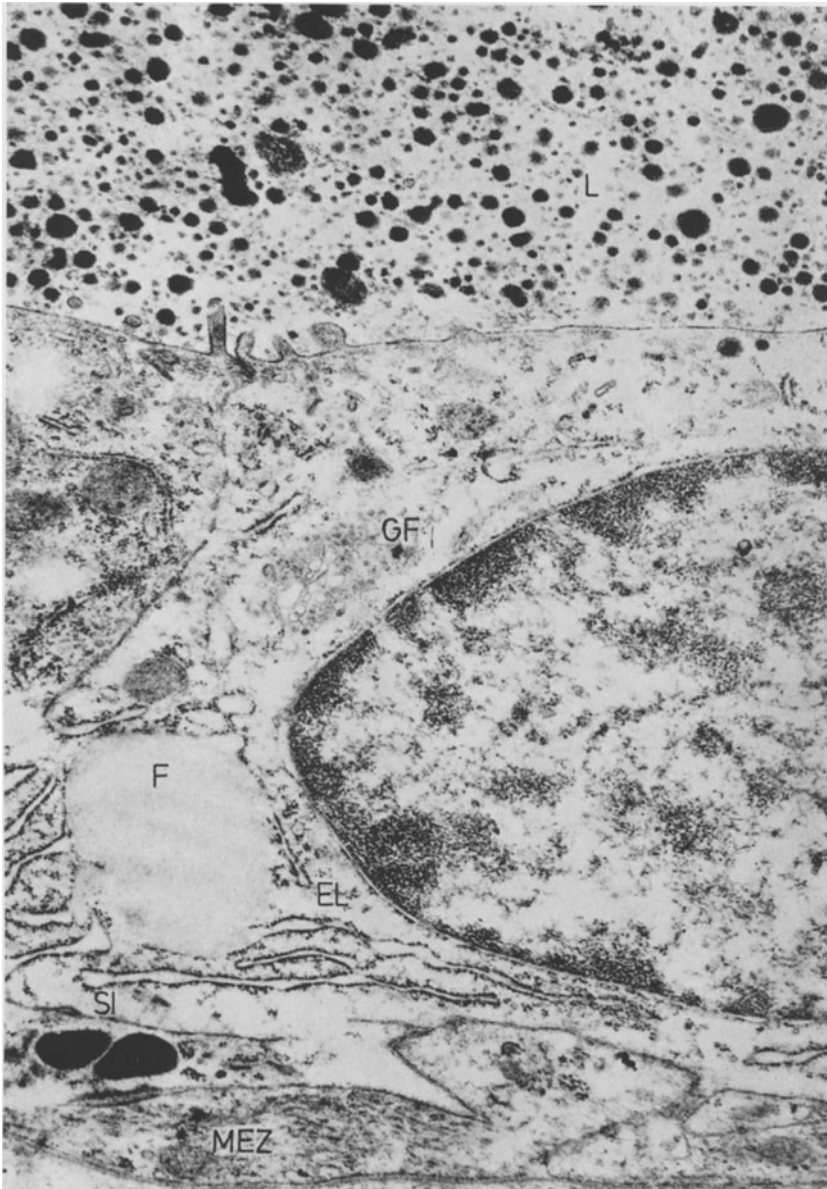


Fig. 18. Partial reproduction of the wall of a glandular alveolus after treatment of a castrated rat with oestrogen for 20 days. In the lumen (*L*) massive small fat droplets; the cytoplasm is transparent. Small Golgi field (*GF*); basally a few ergastoplasmatic lamellae (*EL*) and fat droplets (*F*), siderosomes (*SI*) and myoepithelial cells (*MEZ*).

Record no. 971/66; em. magnification 7,000; in the figure 19,600

Combinations of oestrogen and progesterone differ cytomorphologically in that they produce much more fat. This starts during the first days after injection. After 10 days small droplets will fill the whole cell plasma. The nuclei become deformed and the lumina of the acini become narrower, so that

eventually a pregnancy-like state will result (CHENTSOV, 1964; BÄSSLER and FORSSMANN, 1964; SUETINA, CHENTSOV, SMIRNOVA, and SAMOILOV, 1966). — WELLINGS, and NANDI (1968) succeeded in producing a cell picture in mice that corresponded to normal lactogenesis with synthesis of milk proteins, after triple operation and treatment with oestrogen, progesterone, cortisone, STH, and prolactin.

Unusual lamellated lipid-rich deposits in droplet form with multitudinous transformations to fat droplets were observed after combined oestrogen-progesterone treatment, when corpus luteum hormone preponderated.

From a cytomorphological point of view the structural changes in the glandular epithelium of the mammary gland caused by ovarian hormones are characterized during the first days of administration mainly by an increase of ribosomes, mitochondria, and greater denseness of ribonucleoproteins. An endoplasmatic reticulum then forms, and fat synthesis starts, at first in the base of the cell and then involving the whole of the cytoplasm. Secretion of fat as droplets and retention of secretion may follow on continued stimulation. Recent studies by O. STEIN and Y. STEIN (1966) have supplied information about the high velocity of turnover of triglycerides in the mammary gland. The authors have proved by electron-microscopic autoradiography, that the inclusion of esterified substances into fat globuli takes place 1—3 minutes after injection of labelled fatty acids. The site of reaction is the endoplasmatic reticulum, with mitochondria assisting. Protein synthesis that was assessed in lactating mammary glands by the same method with tritium-labelled leucine took 30 minutes from injection until labelled protoproteins occurred in the Golgi field (WELLINGS and PHILP, 1964; VERLEY and HOLLMANN, 1964; FISKE, COURTECUISE and HAGUENAU, 1967).

The *biochemical mechanisms* of action of the oestrogens are known in some of their essential aspects. The receptor organs used were uterus, vagina, and the anterior lobe of the pituitary, in which oestrogens form a receptor-hormone-protein complex, which triggers off further metabolic reactions. Activation of RNA in the target organ is in the fore. A specific m-RNA is formed, and its information is transferable. The m-RNA is the matrix for the synthesis of specific proteins, which as enzymes direct the cellular metabolism so that energy may be obtained and building elements be synthesized (LAURITZEN, 1965; DELLWEG, 1967). KARLSON (1961, 1962, 1963) had demonstrated the relationship between hormones and gene-conditioned metabolic processes on the model of the hormone ecdyson, which causes insects to cast off their skin. These relationships have also been used to explain other interactions.

JENSON and JACOBSON (1962), KING, GORDON, and INMAN (1965), KING, GORDON, COWAN, and INMAN (1966) have demonstrated by means of labelled steroids the passage of oestrogens through the cytoplasm into the nucleus in the uterus, pituitary, and in a carcinoma of the mammary gland. They have stressed that there is a direct reaction to DNA-synthesis. According to observations by BEATO and DIENSTBACH (1968) the duration of DNA-synthesis remained constant, independent of whether oestrogen or progesterone had

been administered previously. EISENFELD and AXELROD (1965) and GORSKI, NOTEBOOM, and NICOLETTE (1965) described an increase of RNA- and protein syntheses and mechanisms of attachment in the target organs. Androgens, too, caused an increase of RNA (KOCHAKIAN, 1964; WILLIAMS-ASHMAN, 1965).

SEGAL and SCHER (1967) reviewed comprehensively the partial processes of the action of oestrogen on the uterus. These are already known from the biochemical and morphological points of view and may be used as explications of the structural changes in the epithelial cells of the mammary gland induced by hormones.

Hormones of the Pituitary

1. Somatotropin (STH)

Formerly the question whether the site of mammogenic action of STH was at the glandular parenchyma had remained unanswered. LYONS, LI, and JOHNSON (1957) had observed lobulo-alveolar differentiation of the mammary gland of castrated and hypophysectomized rats, when ovarian hormones, prolactin, and STH simultaneously acted upon the gland. Later investigations of the same authors (1958) showed that the mammary gland developed gradually, depending upon mutually complementary combinations of hormones:

Table 4

a) Hypophysectomized		→ delicate system of ducts, no buds
b) Hypophysectomized + ovariectomized	+ STH	→ Proliferation of terminal buds and ducts
c) Hypophysectomized + ovariectomized adrenalectomized	+ STH + oestrone	→ Strong terminal buds -proliferation, ectasia of ducts
d) Hypophysectomized + ovariectomized + adrenalectomized	+ STH + oestrone + DOCA	Proliferation of ducts, formation of terminal buds
e) Hypophysectomized + ovariectomized + adrenalectomized	+ STH + oestrone + DOCA + progesterone + prednisolone + prolactin	→ Lobulo-alveolar growth
f) Hypophysectomized + ovariectomized + adrenalectomized	+ STH + oestrone + DOCA + progesterone + prednisolone + prolactin (i. m. and locally)	→ Lobulo-alveolar differentiation and secretion

STH thus directly stimulates the duct system and the terminal buds, a stimulus that is supported by oestrogen even after adrenalectomy. After triple operation the glandular tubules develop fully when desoxycorticosterone acetate is

given. When the six hormones are administered a status praelactans is produced, during which prolactin gives the impulse towards secretion (LYONS, LI, JOHNSON, 1958). COWIE and LYONS (1959) obtained the same results.

TALWALKER and MEITES (1961) treated virgin rats, 3—4 months old, with cattle STH and cattle prolactin. Some of the animals were castrated and adrenalectomized and received hormone three times daily for 10 days: after administration of 2 mg STH there was considerable growth of tubules with arborization of the glands and formation of buds. After 30 IU prolactin the tubules also grew. Combined administration (1.33 mg STH and 20 IU prolactin) resulted in proliferation of lactiferous tubules and dense lobulo-alveolar development, corresponding to that of pregnancy. The results of triple operation and the combined administration were extensive growth of ducts and lobulo-alveolar development of the mammary gland. MEITES (1965) had similar results and found in castrated and adrenalectomized rats that STH was of importance mainly for the upkeep of growth of ducts. Together with prolactin it promoted the formation of lobuli.

Investigations of the mammarygenesis of hypophysectomized *mice* as compared with that of rats showed considerable differences of reactions of the mammary tissues in several strains of mice. HADFIELD (1957), and HADFIELD and YOUNG (1958) had not observed after hypophysectomy proliferation in response to ovarian hormones alone when they had used strain 2AG. Prolactin or STH alone had also not resulted in proliferation by the combination had. — FLUX (1958) had described intensive growth of ducts in CHI mice on administration of STH with oestrogen and progesterone and lobulo-alveolar growth with prolactin. NANDI (1958a, b) reported after triple operation on C₃H/He Crgl mice that normal growth of ducts occurred only when ovarian hormones, STH, and corticoids were given. When additional progesterone and prolactin acted together with the other hormones alveoli were produced, but secretion was only demonstrated when the ovarian steroids were no longer given. NANDI had also found that in this strain STH replaced prolactin in all phases of mammary development and secretion. The author concluded that progesterone was of greater importance for the development of lactiferous tubules in mice than in rats.

2. Adrenocorticotropin (ACTH)

There are varying assessments of the influence of ACTH on the growth of the glandular structure of the mammary gland: NELSON (1941b) had observed increased growth of the mammary gland in rats after treatment with ACTH; after adrenalectomy administration of ACTH had been unsuccessful. FLUX (1954b) had doubts about these findings. He thought that the crude extracts containing ACTH had been impure, as there had been no changes in castrated mice treated with 0.5—2.0 IU ACTH. The growth of animals that had been pretreated with oestrone, and who had developed lateral outgrowths of the lactiferous ducts, was inhibited by accessory injections of

ACTH. — No changes were found in castrated mice after treatment with ACTH for 21 days (FLUX and MUNFORD, 1957). SELYE (1954a), on the other hand, observed intensive development of the mammary gland and secretion in castrated rats, who had been pretreated with oestradiol, following administration of large doses of ACTH (25 JU twice daily for eight days). Continuing these studies JOHNSON and MEITES (1955) had found after treatment of castrated rats with ACTH for 10 days that the lactiferous ducts had proliferated, and that limited lobulo-alveolar differentiation and secretion had occurred.

3. Extract of the Anterior Lobe of the Pituitary

STRICKER and GRUETER (1928) were the first to study the lactogenic action of extracts of the adenohypophysis. The possible induction of glandular proliferation by administration of extracts of the anterior lobe had been investigated in later studies. According to MIXNER and TURNER (1942a) these extracts are able to increase the action of oestrone in castrated mice and to produce lobulo-alveolar growth. The same authors (1941b) also reported the synchronous influence of raised environmental temperatures (35°C), which decreased the effect of oestrone and progesterone. Extracts of the anterior lobe prevented this decrease. — Investigations by LEWIS, GOMEZ, and TURNER (1942) had shown that it took 16—30 days of treatment to stimulate the growth of ducts in castrated rats, various extracts from pregnant and non-pregnant cattle being used. GOMEZ and TURNER (1937) had obtained the same results. — SYKES and WRENN (1950) had experimented on cows with extract of anterior lobe, which was administered together with diethylstilboestrol and progesterone, and which produced normally shaped lobuli and numerous alveoli at the end of five months. DAMM and TURNER (1961) had found that administration of extract of the anterior lobe and oestradiol benzoate had caused considerable growth of ducts and lobuli in castrated mice. This did not, however, reach the extent seen in the mammary gland during pregnancy. Experiments with the initial residue of the anterior lobe extracts (after removal of tropic hormone) resulted in an increase of DNA in the mammary gland. Extracts from the initial residue, denoted "mammogen C", also triggered off an increase of DNA.

4. Transplants of the Anterior Lobe of the Pituitary

When homologous transplants of the pituitary of 60-day-old female mice were implanted into the inguinal region of mice of similar age, some of whom had been castrated, the non-ovarectomized animals showed lobulo-alveolar growth 120 days later around the transplant. BARDIN, LIEBELT, and LIEBELT (1962) had found some formation of buds in castrated mice. This is a direct mammogenic impulse towards local growth. When transplantation into the anterior chamber of the eye was carried out (BARDIN and LIEBELT, 1964), the mammary glands reacted with lobulo-alveolar proliferation. In hypo-

physectomized mice with transplants only ducts, but not lobuli, developed further. — Simultaneous intramammary transplants of the pituitary and intraocular transplants of the ovary in mice showed after five months the following picture: ovarian transplants had the same effect as stimulation with oestrogen. Transplants of the anterior lobe of the pituitary produced structures that corresponded to combined oestrogen-progesterone treatment. Both transplants together produced lobulo-alveolar proliferation with little secretion (BROWNING, WHITE and GIBBS, 1964). Further studies of this group of research workers (1965) with the same experimental methods showed that hyperplastic nodules were more common after transplantations than in animals with replanted ovaries or ovaries in situ. — BROWNING and WHITE (1965) reported the local stimulating influence of transplants of the pituitary and of the ovaries on proliferation and secretion of the mammary gland.

5. Mammogenic Effect of Transplanted Pituitary Tumours

CLIFTON and FURTH (1960) and TALWALKER and MEITES (1961, 1964) had postulated that tumours of the anterior lobe of the pituitary contained more STH, ACTH, and prolactin and were able to produce full lobulo-alveolar growth of the lactiferous ducts. These studies confirmed the predictions after 40 days or eight weeks.

6. Prolactin (Mammotropin, Luteotropin, Lactation Hormone, Galactin) and the Morphology of the Pigeon Crop Test

STRICKER and GRUETER'S (1928, 1929) discovery considerably advanced knowledge of the physiology of milk secretion as lactationlike secretion was started in castrated, pseudopregnant rabbits, in bitches, sows, and cows by administration of total extracts of the adenohypophysis. RIDDLE and BRAUCHER (1931) identified and isolated this lactogenic protein and called it "prolactin". The authors demonstrated a substance in the adenohypophysis of pigeons, which regulates the proliferative and secretory activity of the crop epithelium. RIDDLE, BATES, and DYKSHORN (1932, 1933) worked out experimentally the basis of the action of prolactin on the pigeon crop as test object. The crop proliferation test in young pigeons is still the best method for the assay of units of prolactin (JUNKMANN, 1957). The structural changes of the crop epithelium are a simple model of morphogenetic hormone action, which may be used to conceptualize similar mechanisms of action in the mammary gland and which is characterized by proliferation and secretion.

Morphology of prolactin action in the pigeon crop proliferation test. The crop of columbides — compared with other bird species — has changed its function, in so far as it serves not only for storage and predigestion of food, but in and during breeding it supplies a milky secretion, rich in fat, for the nourishment of the young. The term "crop milk", which is still used today, was coined by HUNTER (1786), who was the first to investigate these secretory processes. LITWER (1926) proved the holocrine mode of secretion, and lately

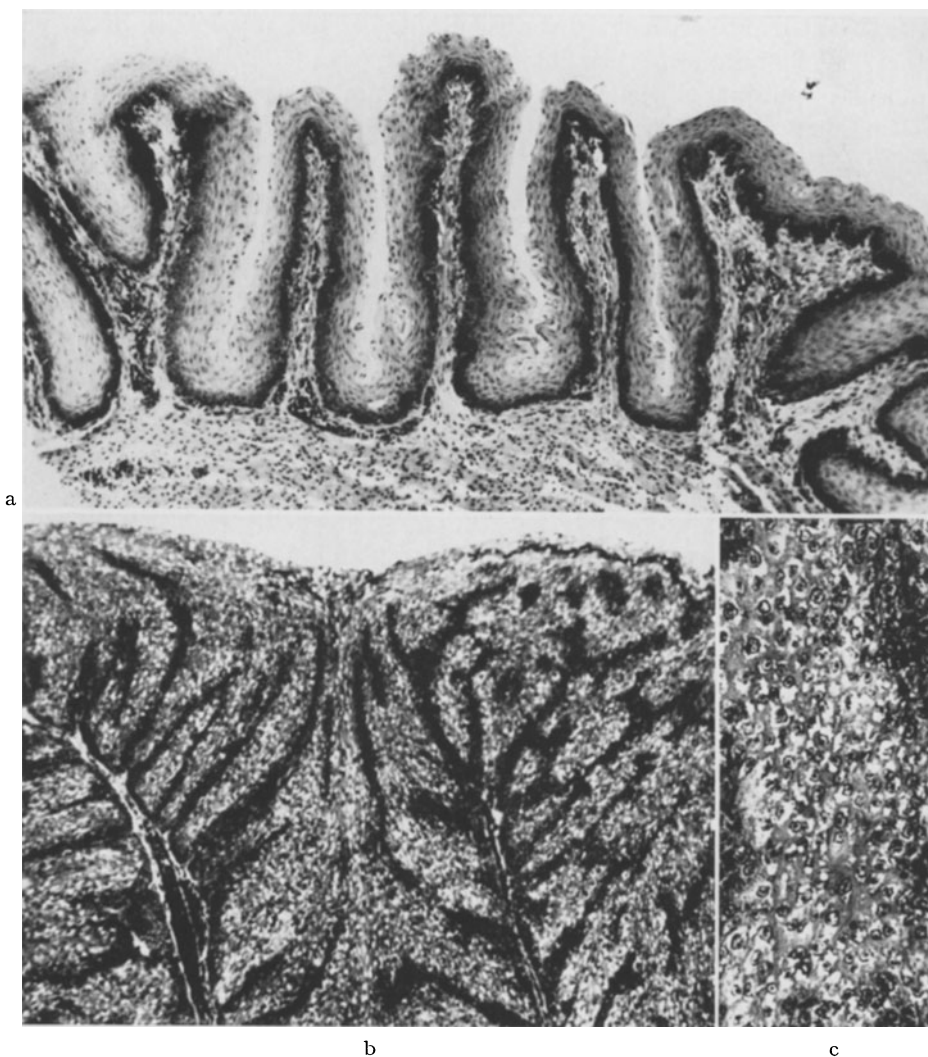


Fig. 19a—c. The effect of prolactin on the pigeon crop. a Resting crop epithelium with formation of folds in the lateral areas of the crop. Formalin, paraffin, HE, magnification $90\times$. b Hyperplasia of crop epithelium with formation of papillary structures and desquamation of superficial cell structures, 90 hours after administration of prolactin (25 IU), subcutaneously in the region of the crop. In the stroma dilated capillaries. Formalin, paraffin, HE, magnification $90\times$. c Enlargement of sector shows transparent gaps in the cytoplasm of the epithelium due to formation of fat droplets. Formalin, paraffin, HE, magnification $230\times$

WEBER (1962) has analysed morphologically the various functional phases of the crop epithelium and has found that there are no morphological differences between normal secretion during care of the young and experimental induced secretion of crop milk. Under the influence of prolactin the epithelium of the lateral areas of the crop proliferates, producing a wide epithelial band that is penetrated by septa, which carry blood-vessels. In the individual cells of

this band there are mitoses, changed shapes of nuclei and nucleoli, extrusion of nucleoli, and formation of fat droplets. The essential characteristics of hormonal action are proliferation, synthesis of fat, and desquamation (holocrine secretion), as shown in Fig. 19.

Electron-microscopic investigations by BÄSSLER and FORSSMANN (1964), FORSSMANN (1965) and by DUMONT (1965) have demonstrated that the cells of the resting crop epithelium have the cytological properties of a syncytium with basal, spinous, and disjoint strata. Under the influence of prolactin the ribosomes in the cytoplasm of the epithelial cells of the basal and spinous strata increase greatly. DUMONT (1965) had also observed polysomes. The increasing basophilia of the cell plasm is concurrent with this early reaction. The basophilia may be observed in the microscope. It goes together with the synthesis of neutral, unsaturated triglycerides in droplet form. After 20 hours the mitochondria increase in size and lose their matrix contrast (FORSSMANN, 1965). The intensive micropinocytosis of the cell membranes and of the capillary endothelium and the increased vascularization of the stroma of the proliferating epithelium clearly seen under the microscope, indicate an intake of precursors of fat synthesis. The epithelial cells, held in place by numerous desmosomes, loosen their connections as stimulation with prolactin continues. The intercellular gaps increase, so that space for intercellular transport of substances is created. When the cells, loaded with fat droplets, part from their neighbours and perish, the gaps near the surface are filled with fragmented microvilli and cell detritus. The detachment of the epithelium at its natural boundaries and the subsequent cytolysis are the criteria of holocrine secretion (BARGMANN, FLEISCHHAUER, KNOOP, 1961), the product of which is the white crop milk indicating the action of prolactin.

LYONS and CATCHPOLE (1933a, b), CATCHPOLE and LYONS (1933), CATCHPOLE, LYONS, and REGAN (1933) were the first to report the promotion of lactation by prolactin in mammals (guinea pigs, rabbits, heifers). They called the purified substance "lactation hormone" or "mamotropin". In further studies of the lactogenic effect by GARDNER and TURNER (1933) the terms "galactin" and later "lactogen" were used. — LYONS (1942) and later MEITES and TURNER (1947) and BRADLEY and CLARK (1956) convincingly demonstrated a direct influence on the glandular parenchyma in pseudo-pregnant rabbits by intracanalicular instillation of prolactin in different doses: those sectors of the gland treated with prolactin reacted with considerable secretion and enlargement of the alveoli, whilst the other sectors showed no reaction. It was impossible to decide with certainty whether endogenous hormones of the anterior pituitary were of importance for lactogenesis. The question therefore arose whether prolactin was *the* lactogenic hormone or merely part of a lactogenic hormonal complex. This concept that had been conjectured by FOLLEY and YOUNG (1941) and underscored by FOLLEY (1956) had been supported by experiments of NANDI (1958a, b) because milk secretion in mice was triggered off by STH and cortisol after triple operations. FOLLEY (1956) and COWIE and FOLLEY (1961) therefore believed that secretion of milk was

due to a pituitary lactogenic hormone complex, the essential and limiting component of which was prolactin.

MEITES and SGOURIS (1952, 1954) had shown in castrated rabbits and LANI (1968) in rats that oestrogen, progesterone, and prolactin had a mutually stimulating and inhibiting action at different quantitative ratios. The antagonism was relative, in other words, dependent upon the individual components. The same goes for lactation, which is inhibited when the activators for mam-mogenesis, i. e. oestrogen and progesterone, are more powerful than the stimulus for secretion, i. e. prolactin, and vice versa (VOSS, 1958).

Comparative histological and histochemical studies of this problem by LANI and BÄSSLER (1967) and LANI (1968) have demonstrated that castrated rats, when pretreated with ovarian hormones and then received simultaneously oestrogen, progesterone, and prolactin, had smaller alveoli and produced less secretion than control groups, to whom prolactin alone had been given after pretreatment lasting for 15 days. The variations in amounts of secretion are depicted in Fig. 10. Fig. 10d clearly shows that the amount of secretion has caused formation of cysts and fibrosing of the intralobular stroma. These are consequences of congestion of secretion. — Simultaneous histochemical investigations of phosphatases and dehydrogenases have shown no differences of reaction between animals that had received either ovarian hormones only or these and prolactin together. At the end of hormone treatment enzyme activity usually decreased, because increasing congestion of secretion had caused cell compression and cytolysis.

Secretion (*galacto- or lactopoesis*) may be maintained only if pituitary function remains undisturbed. Hypophysectomy stops secretion within 24 hours. Even after 4—8 hours alterations of metabolism may be observed in vitro. These changes may be detected biochemically. They correspond to the involu-tional phase of the mammary gland (BRADLEY and COWIE, 1956). The amounts produced in experimental galactopoesis obtained with combinations of hormones reached only 30 % of those of normal lactation (BENSON, COWIE, FOLLEY and TINDAL, 1959).

Recent studies of active placental compounds are of importance for mammo-and lactogenesis, because substances with qualities similar to prolactin and STH may be obtained (AVERILL, RAY and LYONS, 1950; CANIVENC and MAYER, 1953; RAY, AVERILL, LYONS, and JOHNSON, 1955). — HIGASHI (1962) had described two active glycoproteins of the placenta with a molecular weight of 80,000 and 45,000 and with prolactin-like effects on pigeon crops. JOSIMO-VICH and McLAREN (1962) had described similar effects of serum and placenta proteins. These stimulated the crop epithelium and milk secretion and were immunologically related to STH. — RIDDLE (1963), in a review of prolactin, pointed to the growth and weight-promoting effects of prolactin, which related to accessory sex glands and which sensitized the prostate and the seminal glands to androgen (PRICE and WILLIAMS-ASHMAN, 1961). COLE and HOPKINS (1962) in comparative enzymatic studies on mammary tissue after prolactin

action for 14 days reported significant rises of activity of succino-dehydrogenase, alkaline phosphatase, β -glucuronidase, DNA, and nitrogen. —

In view of the numerous observations of the biological activity of prolactin, the question of its biochemical entity and specificity of action has been raised recently. In immunological studies by HAYASHIDA (1962), using the agar diffusion technique of OUCHTERLONY, human prolactin reacted very similarly to STH.

Anti-STH serum contains antibodies both against STH and prolactin. It may be assumed that both compounds consist of one molecule only. The observation that prolactin may promote growth and that STH may be lactogenetic (RIDDLE, 1963) is supported by experimental studies by FORSYTH, FOLLEY and CHADWICK (1965): it was shown by means of the intraductal rabbit test and the pigeon crop test that human STH was strongly lactogenetic. The crop epithelium reacted to a lesser degree than the mammary gland of the rabbit. On the basis of these results it is at present under discussion whether the growth hormone is the solely hypophyseal lactogen.

Questions of the hypothalamic inhibition of synthesis and incretion of prolactin cannot be dealt with here.

7. Oxytocin

Experimental experience indicates that this hormone of the posterior lobe of the pituitary is of no importance for mammogenesis. The stimulating influence of oxytocin on the system of myoepithelial cells and on the discharge of prolactin of the adenohipophysis is considerable according to recent observations, so that two effects and sites of action ought to be distinguished.

a) Galactokinetic Effect

The path of secretion from the site of production of the glandular alveolus up to the mamilla is several centimetres long both in man and animals. Negative sucking pressure is too small to overcome this distance. In the human infant it is 4—14 cm initially. During continuous stimulation by sucking it may rise to 140 cm water (VOLKMANN, 1951), so that sucking can move milk from the lactiferous ducts and sinuses only. A *vis a tergo* is needed for the outflow of greater quantities of secretion from the periphery of the gland. This is supplied by the functioning of the myoepithelium of the alveoli and the small lactiferous tubuli. This cell system, which has arisen out of the glandular epithelium has special functions (WATZKA, 1955). It is the receptor and transformer of the oxytocin effect on the glandular alveolus. For the *mechanism of milk outflow* the term "milk let down" (for the oxytocin effect "milk let down factor") has been used, which according to FOLLEY (1947, 1956) and COWIE, FOLLEY, CROSS, HARRIS, JACOBSON, and RICHARDSON (1951), should be replaced, however, by the term "*milk ejection reflex*", as it is preceded by active cell work.

The structural formula of oxytocin, an octopeptide, was discovered in 1953, and the compound was synthesized in the same year by DU VIGNEAUD *et al.*

(1953 a, b). It is produced in the paraventricular nucleus. The hormone reaches the posterior lobe of the pituitary as neurosecretion (BERDE, 1959). The short duration of action, with a half-life time of approx. three minutes (SAAMELI, 1961), 9.7 minutes after blocks of the kidneys (CHAUDHURY and WALKER, 1957), is due to an inactivating enzyme, oxytocinase. The oxytocinolytic property of an aminopeptidase of the plasma during pregnancy increases up to delivery and then immediately decreases to its initial value (BERDE, 1959). BERDE and CERLETTI (1960) obtained two reaction types in the lactating mammary gland by pharmacological doses: intravenous individual injection caused a short rise of mammary internal pressure; long-term infusion after a latency period of about one minute caused a tonic reaction with persistent rise of pressure or rhythmic variations of pressure. The effect may be temporarily interrupted by adrenaline.

The secretion and the activity of oxytocin are maintained by a neurohumoral reflex arc, which is triggered off by tactile stimuli of the suckling young animal at the mamilla and which enters the hypothalamus as an afferent nerve arc. Oxytocin is liberated there via the neurohypophysis. It acts by humoral pathways on the myoepithelia, these were called the motor apparatus of the mammary gland by ZAKS (1962). This explains the synergic action. — Two further reflex arcs were proposed by ZAKS (1962): a segmental, short arc for the varying dilatation and contraction of the lactiferous ducts during milk transport and a cortical arc to explain psychic influences on secretion. —

Description of *the morphology of the oxytocin action* is subject to knowledge of the myoepithelial cells and their normal behaviour. Their structure was elucidated microscopically by selective staining methods or in-vivo observations (LINZELL, 1955). HAMPERL (1940) and KUZMA (1943) had used silver impregnation to discover abnormality of these cells. It became possible then to assess the myoepithelia directly by silvering of their basal membrane. By means of direct silvering they were shown by RICHARDSON (1949) in the udder of the goat, and by LINZELL (1952, 1955) in the alveolar wall. DEMPSEY, BUNTING, and WISLOCKI (1947), SILVER (1954), LEESON (1960), BÄSSLER, SCHÄFER and PAEK (1967), and BÄSSLER and BRETHFELD (1968) have obtained similar results by the essay of alkaline phosphatase, using the azodye method (GÖSSNER, 1959) and taking into account the varying functional stages of the alveoli (Fig. 20). The changes of structure of the myoepithelial cells during pregnancy were shown to have a uniform pattern, in that delicate cell processes increased in size during lactation, but became denser during involution. The increase of size in congestion of milk may lead to rupture of the cell processes, which then surround sectors of the alveolar surface only. In experimental work under the influence of sex hormones myoepithelial cells developed with the same enzyme-histochemical and morphological properties as during normal functioning.

The area occupied by myoepithelial cells increases concurrently with the enlargement of the alveoli during pregnancy, lactation, and acute galactostasis. During involution this is reversed. Under the influence of oxytocin the alveoli

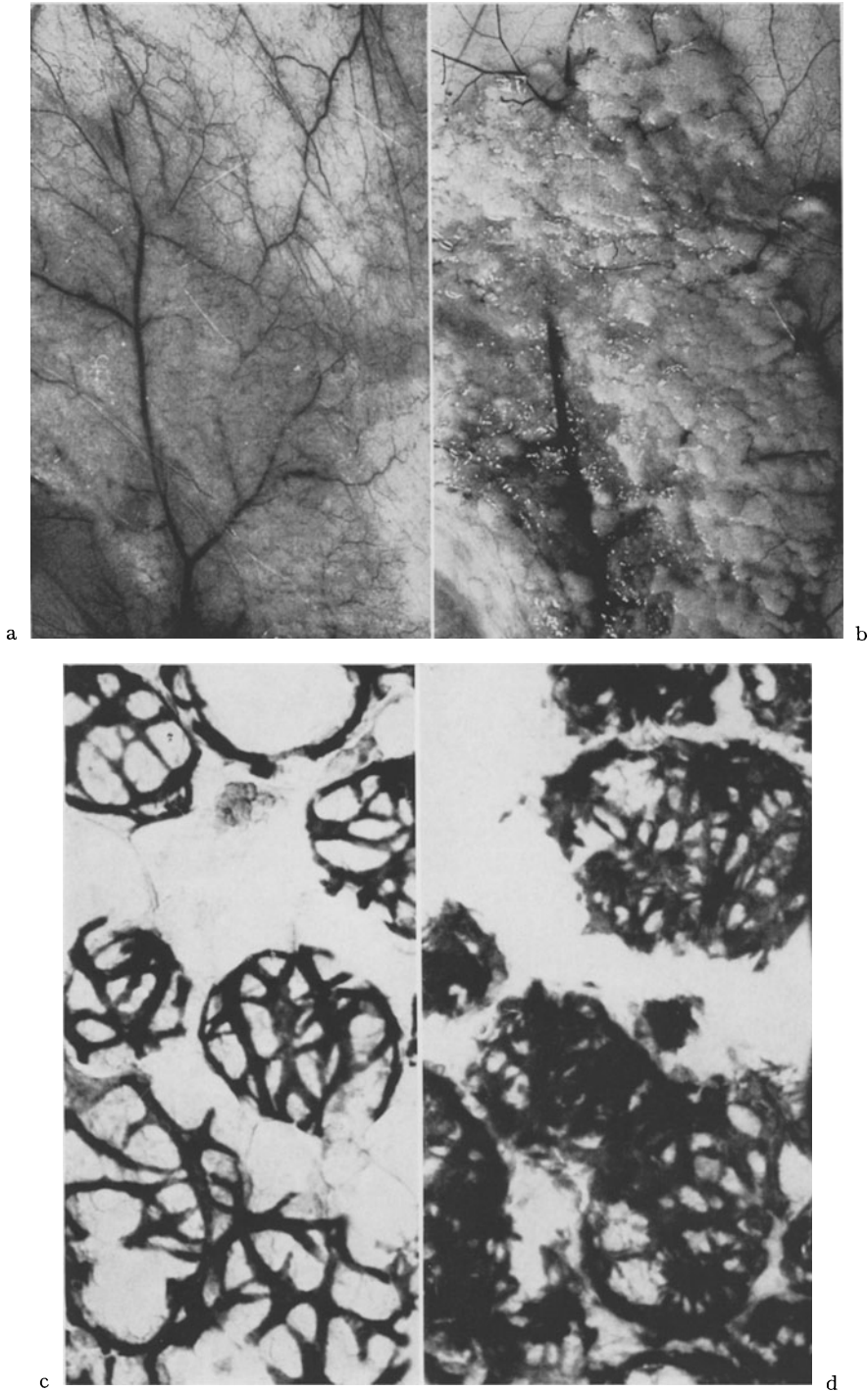


Fig. 20. a Lactating abdominal mammary gland of the rat with considerable vascularization. b Condition after syntocinon injection, two minutes after beginning of injection. Contraction of circumscribed areas of the gland and dilatation and filling with secretion of the prominent glandular fields. Representation of myoepithelial cells by determination of alkaline phosphatase (azodye method). c Lactation with dilated alveoli. d Contracted state of the myoepithelium after injection of syntocinon. Broad irregular cell structures and diminished alveoli. Magnification $245 \times$

diminish in size, whilst the myoepithelium increases in area to one-third more than during lactation.

Electron-microscopic investigations of the myoepithelium of the mammary gland by TAKAHASHI (1958), LANGER and HUHNS (1958), HAGUENAU (1959), and MURAD A. V. HAAM (1968) were restricted to morphological analysis of these cell types, which resemble those of the salivary glands (TAKAHASHI, 1958; MYLIUS, 1960; TANDLER, 1965; TAMARIN, 1966), of the eccrine sweat glands (HIBBS, 1958; MUNGER, 1961; TERZAKIS, 1964; ELLIS, 1965), of the apocrine sweat glands (TAKAHASHI, 1957; MUNGER, 1964, 1965), of HARDER'S gland (CHIUQUOINE, 1958), and of the extraorbital lacrimal gland (LEESON, 1960a, b).

The fine structure of the narrow cords of cells, which surround the alveoli, is characterized by its myofilaments, which enclose the nuclei. The mean diameter of the filaments is 50—90 Å. It is of similar dimensions both in the mammary gland and in the salivary gland (TAMARIN, 1966) and of the same dimensions as in actin fibres, as determined by NEEDHAM and SHOENBERG (1964). Contrast-rich cords, which recall the Z-membranes of the skeletal musculature, are interlaced with the filaments. Dense bundles are seen along the cell membranes which correspond to sites of insertion in the sense of hemi-desmosomes. The motor cell system of the mammary gland develops most abundantly during lactation, and differences in the cell structure that depend upon the degree of filling of the alveoli may then easily be recognized. Even during transient conditions of stasis cross-sections of the myoepithelia may hang saddlewise between extended and "drooping" alveoli. When galactostasis is more permanent, these cells form a resistant stratum that still surround the alveoli, even though the glandular cells have largely disintegrated (BÄSSLER, 1961).

In experiments when oxytocin is administered and is acting on the lactating mammary gland of the rat the contraction effect manifests itself under the microscope (Fig. 20a, b) by a retraction of circumscribed glandular areas and by secretion being packed in the lactiferous ducts, which may show variciform distension. Histologically and histochemically alveoli and lobuli shrink and interstitial oedema may develop (Fig. 20c, d). Irregularities of alveolar contours prove electron-optically to be prolapse of the cytoplasm, which protrudes between contracted myoepithelial cells. As there is no proper co-ordination between contraction and simultaneous secretion in experiments these phenomena appear more conspicuous than normally. The contraction stimulus, when observed in the electron microscope, manifests itself by denseness of the intracellular myofilaments, leading to retraction and serration of the sites of insertion at the cell membrane. The cords of cells surrounding the alveoli shorten, and the diameter of the alveoli is therefore lessened. Emptying of the alveoli is followed by fresh synthesis of milk products and secretion into the alveolar lumen.

b) Galactopoetic Effect

SELYE (1934), BENSON and FOLLEY (1956, 1957a, b) and DESCLIN (1956a, b) found that oxytocin may inhibit the involution of the mammary gland.

Experience indicates that it is unlikely for oxytocin to act directly on the mammary glandular cells. It may thus be assumed that prolactin stimulates by indirect action, because under identical condition this hormone in particular produces the same results (BENSON, COWIE, FOLLEY and TINDAL, 1959). This is supported by the fact that the effect is not observed in hypophysectomized animals (BENSON and FOLLEY, 1956b, 1957).

The angioarchitectonic relationships between the hypothalamus, the stalk of the pituitary, and the adeno- and neurohypophysis suggest the regional "portal" circulation as an explanation for the direct influence of neurohypophyseal substances on the adenohypophysis (GREEN and HARRIS, 1946/1948). GROSVENOR and TURNER (1957a, b) were opposed to these assumption, because of the fall of the level of prolactin when excretion of milk ceases, i.e. when involution begins.

Hormones of the Adrenal Cortex

HÖHN'S (1957) experiments have provided evidence for the importance of the steroids of the adrenal cortex for growth and differentiation of the mammary gland: guinea pigs react to administration of oestrogen by formation of lobuli; after adrenalectomy, however, only by proliferation of ducts. Numerous investigations have shown the variations of responses of the mammary gland to hormones of the adrenals, supposed to depend, according to AHRÉN and JACOBSON (1957), upon the initial hormonal condition of the species and also upon the chemical structure of the hormones.

SELYE (1954a) was the first to demonstrate the synergic reaction to cortisol (500 mg/d) and oestradiol (5 mg/d) in ovariectomized rats. There was maximal development of gland, maximal secretion, and maximal dilatation of the alveoli, corresponding to the lactation phase. Administration of hydrocortisol acetate (0.5 mg/d) alone to noncastrated rats produced proliferation of ducts after gonadectomy and adrenalectomy there was only slight growth of the mamillae. When oestradiol was administered simultaneously, the gland was developing markedly (SELYE, 1954b). — FLUX (1954) had observed both antagonistic and synergistic reactions of the hormones of the adrenal cortex: cortisone inhibited the growth of castrated mice when they had been pretreated with oestrone. After administration of desoxycorticosterone acetate (DOCA) the growth stimulus, initiated by oestrogen, became more intense. — MUNFORD (1957) reported dose-dependent reactions, in that combinations of oestrone and small quantities of cortisol caused greater glandular growth than cortisol.

According to JOHNSON and MEITES (1955) non-castrated rats react to cortisol or cortisone with proliferation of ducts and lobuli. Both formation and excretion of secretion were more intense when cortisone had been given. The findings of JOHNSON and MEITES (1956) seem to support the assumption that cortisone will promote lactation and that hydrocortisone acetate will cause a proliferating mammary gland of pregnancy to secrete on the 16th—19th day

(TALWALKER, NICOLL and MEITES, 1961). Cortisone may inhibit involution after weaning in lactating rats (JOHNSON and MEITES, 1957).

Other points of view have been presented by AHRÉN and JACOBSON (1957) in extensive studies. They had shown that cortisone stimulated increase in size and increased proliferation of duct epithelium in hypophysectomized animals, although differentiation was not normal, even when ovarian hormones were given in addition. — Nonhypophysectomized rats merely secreted without there being growth; this occurred only when ovarian hormones were administered in addition. These observations indicate that cortisone chiefly promotes the growth of alveoli and secretion, although the intensity of the metabolic action of cortisone limits any inhibitory effect or deformity of the gland (COWIE and FOLLEY, 1961). — Hydrocortisone acetate in late pregnant rats induce an increase of RNA but not of DNA (FERRERI and GRIFFITH, 1969).

SMITH and BRAVERMAN (1953) have described experiments carried out on immature rats after castration. They found dosedependent reactions on combined treatment. Earlier investigations on mice gave similar results (GARDNER, 1940; LEONARD and REECE, 1942; SMITHCORS and LEONARD, 1943). — The results of these investigations show that steroids also have a direct mammotrophic effect. Experiments on the synergic action of various combinations of hormones have shown that the development of the mammary gland is encouraged by simultaneous application of adrenal cortical hormones.

Testosterone

LAQUER (1943) was the first to demonstrate the effect of male sex hormones on the mammary gland of *non-castrated female rats*. He brought together experimental animals (2.5 mg testosterone propionate every other day; a total of 25 mg in 20 days) and young animals, aged 6—10 days. Four of the six experimental animals were able to breastfeed their adoptees on the second and third day after the start of the injections. The author by comparative histological investigation pointed to the similarity of the mammary structure in pregnancy, lactation, and on stimulation by testosterone, when a status praelactans was obtained. After administration of 40 mg testosterone and suckling of the young animals for 10 days the mammary glands could not be distinguished from normally developed lactating glands. — With increasing dosage and duration of administration the production of both acini and secretion increased. At the same time progressive atrophy of the corpora lutea was observed, which counteracted secretion. — LAQUEUR and FLUHMAN (1942) further investigated the action of testosterone on the genital cycle, when proliferation of ducts and acini was observed during oestrus. — According to FORBES (1942) the testosterone effect is not noticeable in prepubertal animals.

Numerous studies of castrated rats are in existence, based on work by MCEUEN, SELYE and COLLIP (1936), who compared mammary development in male animals. On the 48th day of life non-castrated controls showed regular development of small buds, alveoli, and secretion. This has been confirmed by

ASTWOOD, GESCHICKTER and RAUSCH (1937). The castrated animals had small glandular tubuli without the characteristics of secretion and proliferation.

Further experimental studies of similar arrangements have produced similar results (Table 5). The drugs were administered by the intramuscular or circum-alveolar (local) routes.

Table 5

Single dose	Duration of administration	Alveoli	Cysts	Authors
0.05 mg	21 days	(+)	—	AHRÉN and ETIENNE (1959)
0.15 mg	21—23 days	+—	—	AHRÉN and HAMBERGER (1962)
0.2 mg	23 days	+		SELYE, MCEUEN and COLLIP (1936)
	15 days	++		REECE and MIXNER (1939)
0.3 mg	21—23 days	++		AHRÉN and HAMBERGER (1962)
0.4 mg	18 days	++		MCEUEN, SELYE and COLLIP (1936)
0.5 mg	8—30 days	++	(+)	AHRÉN and ETIENNE (1959)
	60 days	+++	(+)	ASTWOOD, GESCHICKTER and RAUSCH (1937)
0.75 mg	21—23 days	+++		AHRÉN and HAMBERGER (1962)
1.00 mg	25 days	+++		NELSON and MERCKEL (1937)
1.50 mg	21—23 days	+++		AHRÉN and HAMBERGER (1962)
2.50 mg	30 days	+++	+	AHRÉN and ETIENNE (1959)
2.50 mg	10 days	+++	++	MEYER (1967)
5.0 mg	5 day	++	+++	MEYER (1967)

Increasing individual doses given to female and male castrated rats, the duration of the experiment being alike, caused increasing lobulo-alveolar development of the mammary gland, secretion, and — with larger doses — formation of cysts. — MEYER (1967) and I were able to achieve this after five days, having injected large doses. We believe this to be due to the secretory impulse that starts immediately (Fig. 21 a). Female animals reacted with simultaneous dosedependent production of udders.

Studies by HAMBERGER and AHRÉN (1964) have shown that the stimulation of the glandular parenchyma by testosterone depends on intact function of the adrenal cortex: after adrenalectomy male sex hormone was effected only when cortisone was administered as well. Oestrogen as a substitute failed. Adrenalectomized and hypophysectomized animals did, however, react to combinations of STH and testosterone. — Similar investigations by JACOBSON and NORGREN (1965) in adrenalectomized and gonadectomized rats resulted in lobulo-alveolar growth only provided oestrogen (0.05 mg) and cortisone acetate (0.125 mg) were added to testosterone (0.1—0.2 mg).

There seems to be general agreement that the mammary gland of hypophysectomized rats is not stimulated although large doses may have immediately been given (MCEUEN, SELYE and COLLIP, 1937; LEONARD and REECE, 1942; LEONARD, 1943). The last author merely mentioned hyperplasia of ducts and swelling of nuclei.

This was quite different after castration and hypophysectomy and treatment with testosterone: REECE and LEONARD (1942) and AHRÉN (1959a, b) mentioned hyperplastic ducts and epithelia, and DONOVAN and JACOBSON (1960) described also a coloured secretion. This is in conformity with observations of my own (Fig. 21 b). — A large number of further combinations of the compounds did not induce lobulo-alveolar differentiation of the mammary

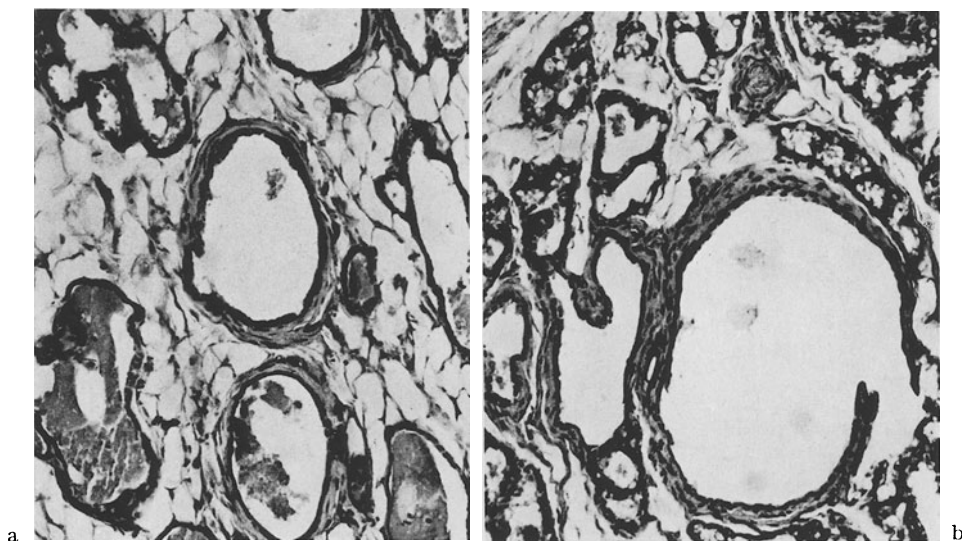


Fig. 21 a and b. Action of testosterone on the mammary gland of castrated female rats. a Strong lobular hyperplasia with formation of cysts and secretion after 2.5 mg/5 d. b Dilatation of duct, formation of alveoli and lobuli with secretion and castrated, hypophysectomized animal after treatment with testosterone (0.5 mg/10 d). Formalin, paraffin, HE, magnification 230 ×

gland after the preliminary operations, except when testosterone was administered together with STH (REECE and LEONARD, 1942; AHRÉN, 1959a, b). The following combinations produced hyperplasia of lactiferous ducts and of epithelial cells with variable amounts of secretion:

Table 6

Combinations of hormones	Alveoli	Hyperplasia of ducts	Secretion	Authors
Testosterone + Insulin	—	+	—	AHRÉN and ETIENNE (1959)
Testosterone + Insulin + Cortisone	—	+	+	DONOVAN and JACOBSON (1960)
Testosterone + Insulin + Cortisone + Thyroxin	—	+	(+)	DONOVAN and JACOBSON (1960)
Testosterone + Insulin + Cortisone + Oestrone	—	+	+	JACOBSON (1962)
Testosterone + Prolactin	—	+	++	AHRÉN (1959b)

BENGTSON and NORGRÉN (1961) studied the effect on *rabbits*. The authors had combined testosterone and oestrogen at different dosages and a time of observation of up to 56 days, and described differences in arborization and secretion of the glands.

HEUVERS WYN, FOLLEY and GARDNER (1939) and FLUX (1954) described in *mice* proliferations of the tubular system with buds in castrated and non-castrated animals. Alveoli were not observed. Testosterone had no stimulating effect in mice after castration and hypophysectomy (FERGUSON and VISSCHER, 1953; DORFMAN and SHIPLEY, 1956). Androgen together with extracts of the pituitary or STH promoted the growth of the mammary gland. Experiments by ARHELGER and HUSELY (1951) demonstrated the antagonism between androgen and oestrogens by implanting vaginal tissue into male animals, castrating some and treating them for four weeks with oestrogens (0.5 g/d). Proliferation of the mammary gland was found only in castrated animals, in whom the action of oestrogen had not been abolished by endogenous androgen. The implanted vaginal skin reacted with keratinisation and formation of mucous membrane, as was to be expected.

BOTTOMLEY and FOLLEY (1939) studied mammary glands and udders of immature castrated and non-castrated guinea-pigs. They pointed to the proliferation of ducts and production of alveoli and also to the fact that the position of the hydroxyl groups on C₃ or C₁₇ and the double bonds in the androgen molecule were of importance for the development of the udders.

FOLLEY, GUTKELCH and ZUCKERMAN (1939) found production of alveoli only when rhesus monkeys received large doses (1.69 g for 151 days). VAN WAGENEN and FOLLEY (1939) had the same results with castrated female rhesus monkeys.

Thyroxin

The hormone of the thyroid gland belongs to a group of active compounds that influence the general metabolism and thus by indirect action proliferation of the mammary gland or that by stimulation of other hormones promote the secretion of the mammary gland. According to LEONARD and REECE (1941) and MEITES (1959a) the development of the mammary gland, ectasia of the ducts, and formation of buds may be increased in rats by thyroidectomy, whilst in mice hypothyroidism appears to inhibit the development of the gland (FOLLEY, 1952, 1956). On the other hand, CHEN, JOHNSON, LYONS, LI and COLE (1955) and LYONS, LI and JOHNSON (1958) pointed out that rats showed no signs of thyroxin deficiency after hypophysectomy, adrenalectomy, thyroidectomy, and administration of oestrone, progesterone, STH, prolactin, and STH. The action on the gland is thus indirect, not direct. — Measurements of DNA (MOON and TURNER, 1960) in castrated rats with mild hyperthyroidism gave higher values in mammary glands that had been stimulated by ovarian hormones than in controls with undisturbed thyroid function. GRIFFITH and TURNER (1961b) reported that thyroxin produced similar growth-promoting

stimuli, which produced a development of the mammary gland in pregnant animals that was 22 % greater than in rats that had not been pretreated with thyroxin. — JACOBSON (1959, 1960) had described in castrated and hypophysectomized rats increased development of ducts under the influence of thyroxin after administration of oestrone and progesterone. The importance of hormonal synergism for glandular growth was the object of further studies by DONOVAN and JACOBSON (1960a, b). According to GOMEZ and TURNER (1937) small doses of thyroxin are ineffective in hypophysectomized animals. — MIXNER and TURNER (1942c) had found that glandular differentiation was 25 % greater in mice who had been given optimal doses of thyroxin than in euthyroid controls. — MOON (1962) had treated castrated and thyroidectomized rats with ovarian hormones following equal pretreatment. He obtained a significant rise of DNA values of the proliferated mammary gland and a change of morphological structure by progressive treatment with thyroxin. Oestrone, progesterone, and thyroxin started secretion in the lobuli and thus produced a picture of early lactation. The synchronous rise of the LTH level when thyroxin was administered justified the assumption that thyroxin promoted both the production and the secretion of lactogen and somatotropin. — This was supported by in-vitro studies by NICOLL and MEITES (1963). The authors were able to increase prolactin secretion of explantate cells of the adenohypophysis by thyroxin, but not by insulin. Recent observations of the pathogenetic relationship between disorders of the mammary gland and the thyroid gland have shown a positive syntropism between proliferating mastopathy and disorders of the thyroid gland, together with an increase of the survival rate of carcinoma of the mammary gland (HUMPHREY and SWEDLOW, 1964). — According to epidemiological studies the number of carcinomas of the mammary gland will increase under conditions of iodine deficiency and hypothyroidism (ESKIN, BARTUSKA, DUNN, JACOB and DRATMAN, 1967). These authors found in experiments that iodine deficiency potentiated the simultaneous effect of oestrogen on the mammary gland of rats, whilst testosterone triggered off an increase in cellular and cystic hyperplasia. The typical morphological findings, characterized by cysts, epithelial proliferation, and secretion, were further intensified by iodine deficiency and propylthiouracil. When the mammary gland was stimulated by hormones in the same manner, different functional states of the thyroid gland caused different glandular structures in cystic hyperplasia. The authors were able to prove statistically that carcinoma of the mammary gland increased when endemic goitre with hypothyroidism increased. Vice versa, the number of carcinomas of the mammary gland in conjunction with thyrotoxicosis was smaller than when in conjunction with euthyroidism or myxoedema.

Parathyroid Hormone and AT 10

The high mineral content of milk, especially the content of calcium, the level of which is 10 times higher than in the blood, makes it appear likely that the epithelial bodies have an influence on lactation. COWIE and FOLLEY

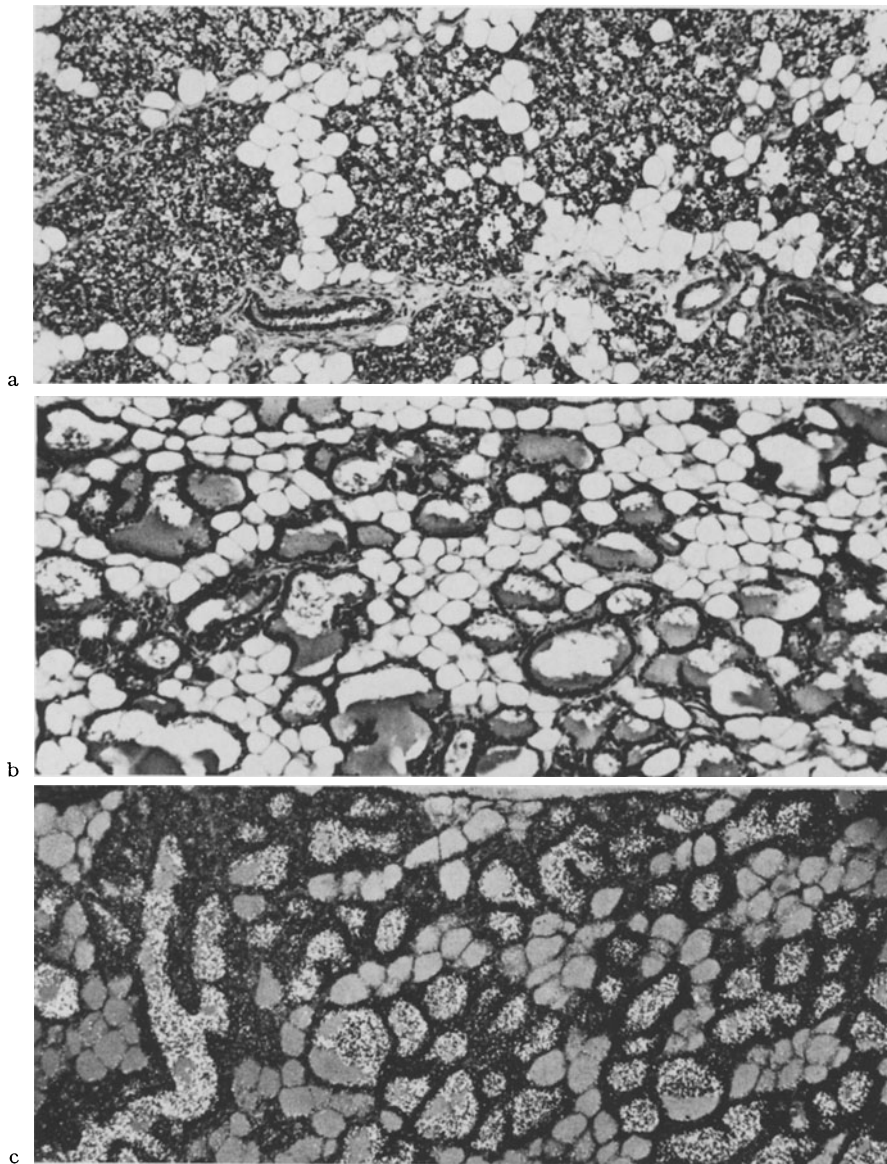


Fig. 22a—c. Effect of AT 10 on the mammary gland after stimulation with hormones. a Castrated female rat. Lobular proliferation with synthesis of fat and little secretion after treatment with 5γ Progynon and 50 mg Proluton for 10 days. Formalin, paraffin, HE, magnification $90 \times$. b Castrated female rat. Lobular proliferation and intense secretion with formation of alveoli filled with secretion after treatment with 5γ Progynon and 50 mg Proluton and AT 10 for 10 days. Formalin, paraffin, magnification $90 \times$. c Sector with representation of calcium enrichment in the secretion after Voigt in semi-polarized light. Alcohol, paraffin, Voigt's staining, magnification $90 \times$

(1945) had found that secretion after parathyroidectomy alone decreased nearly as much as when the thyroid gland had been removed simultaneously. MUNSON (1955) observed 24 hours after parathyroidectomy a rise of calcium

in milk with decrease of calcium in the serum. MOSIMANN (1955) had described increased calcium contents of milk after lactation had been started artificially by oestrogen. The enlargement of the volumes of the nuclei in the parathyroid gland indicates increased activity under the influence of hormones. — According to DJOJOSOE BAGIO and TURNER (1964a), dihydrotachysterol is a substitution of parathyroid function. Comparisons between parathyroid extracts, dihydrotachysterol, and calciferol have shown a general increase of lactation due to increased mobilization of serum calcium and increased intake of feeds (DJOJOSOE BAGIO and TURNER, 1964b). Combinations of dihydrotachysterol (AT 10), oestrogen, and progesterone, given to rats after ovariectomy, thyroidectomy, and parathyroidectomy (v. BERSWORDT-WALLRABE and TURNER,

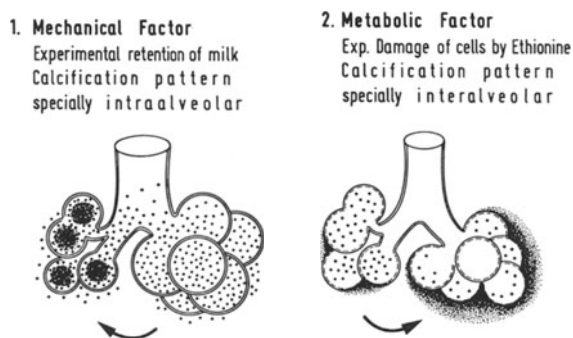


Fig. 23. Schematic representation of the experimental calcifications of the female mammary gland

1960a, b) and parathyroid extracts (DJOJOSOE BAGIO and TURNER, 1964c), raised the DNA content of the mammary glands. BRANDT and BÄSSLER (1968, 1969) had found in the mammary gland of the rat that had been stimulated by oestrogen and progesterone an increase of secretion by AT 10 on the 10th day of injection to the extent that alveoli developed, which were full of secretion (Fig. 22). The calcium content of the secretion was strongly positive, as shown histochemically (Fig. 22c). These studies demonstrate the stimulating action of AT 10 on secretion in the lobuli. This relates both to lobular distension and to the changed qualitative composition of the secretion. The importance of AT 10 for calciphylactic reactions of the mammary gland in experiments and for calcifications in the human mammary gland has been the object of recent studies by BRANDT (1968). According to the author two types of calcification may be distinguished: *intra-alveolar calcification* after *congestion of secretion* and *interstitial calcification* after experimental metabolic cell damage. I was able to produce the last in experiments by means of ethionin (Fig. 23).

Insulin

Insulin belongs to the group of hormones that are not directly mammogenic. It promotes proliferation and differentiation of the mammary gland when combined with other hormones. Experimental studies have shown that

oestrogen, progesterone, prolactin, STH, and further hormones are necessary to trigger off complete development of the gland (BENSON, COWIE, FOLLEY and TINDAL, 1959). On the basis of observations by SALTER and BEST (1953) regarding a possible mammogenic effect of insulin in hypophysectomized rats AHRÉN and JACOBSON (1956, 1957), AHRÉN and ETIENNE (1958), and AHRÉN (1959a) have shown that insulin, when administered for a long time, is able together with ovarian hormones to stimulate growth of the tubules. It may be assumed that insulin enters beneficially into the general metabolism and that it increases the reactivity of mammary tissue towards oestrone and progesterone. Cortisone diminishes this effect, thyroxin increases it (AHRÉN and JACOBSON, 1956; JACOBSON, 1959, 1961).

Relaxin

Relaxin, most of which is produced in the ovary and which becomes active during pregnancy, is supposed to influence the development of the mammary gland (SMITH, 1954). Little is known about its effect on secretion. According to COWIE (1961) relaxin diminishes the milk yield of goats after castration and pretreatment with oestrone and progesterone. It is also assumed that this hormone is of importance for the contraction of the myoepithelium in sheep, but not in cows and rats.

Summary

Present opinion is that the morphogenesis of the female breast is regulated by a complex of hormones, the direct and indirect action of the various substances being complementary. The essential hormones are those of the ovary, *estrogen* and *progesterone*, and the *pituitary secretions*, *prolactin*, *STH* and *ACTH*. An indirect mammatrophic effect is exerted by thyroxine, insulin and the glucocorticoids by stimulating the metabolism in general. The full development of the mammary gland is achieved by the synchronous operation of this hormonal complex, not by any single hormone.

The *proliferation of the duct system* is triggered by estrogen, STH and the adrenocortical steroids.

Lobular-alveolar development is due to the synergic action of the ovarian hormones, STH, steroids and prolactin. Secretion of prolactin is stimulated by estrogens, thyroxine and steroids (STEINBECK, 1969).

V. Pathology of Effects of Hormones on the Human Mammary Gland

It is reasonable to expect that the results of the many experimental investigations of hormonal mechanisms of regulation of the mammary gland would explain disorders of the human mammary gland. This has formerly been taken into account to a small extent only, because the study of the actions of hormones on lactation and their therapeutic control was the primary concern.

Obviously, the physiology and the biochemistry of the various phases of nutritive function of the mammary gland have developed to a greater extent than those of disorders of the mammary gland. In comparison, endocrinological premises, by which the pathological developments of the human mammary gland may be interpreted, are still unsatisfactory. Difficulties of morphological interpretation arise from the great variability of the various reaction types of the lobuli and also because there is a lack of attempts at matching in individual cases hormonal status and structural changes. For this reason pathogenetic interpretations depend largely on analogies from animal experiments and on laws obtained by comparison of similar events by generalizing induction (M. HARTMANN, 1956). Morphogenetic patterns have been constructed from investigations of different species, which have then been transferred to human pathology. These patterns are co-ordinated with disorders of the human mammary gland, which are due to endocrine dysregulations. Pathomorphogenetic analysis of dysplastic mammary disorders must take into account the structural and functional individuality of this organ, the pathoclysis of which coincides with the phases of hormonal stimulation, and the possibilities of dysregulations during sexual maturation and involution. An essential precondition for pathohistological assessment would be a type classification of glandular structure, related to age and statistically verifiable, mainly of microscopic units which would serve as measure. The lack of this is at present balanced by general morphological findings, and the "harmonious" regular structure of the epithelium and the stroma of the lobuli is used as criterion. LETTERER (1948) has coined the terms "concordance" for the normal and "discordance" for the disordered structure of the gland, in adaptation from the terms used for changes of the endometrium. The disorders may concern the whole organ or parts only. The local dysregulations pertain to individual gland structures that have their own terminal flow path and are interpreted as localized misguidance of hormonal impulses. It remains open whether the terminal flow path or the whole of the angioarchitecture of the mammary gland are responsible for local dysplasias. The frequency of the localization of disorders of the mammary gland in the upper outer quadrant has not been explained and may well be a consequence of the particular type of vascularization of this region of the gland.

It is important, too, for morphological assessment to determine whether the mammary gland is stimulated by accessory endocrine in the state of tubular or lobular differentiation. The strength and quality of the hormones is, of course, also of importance. Metaplasia of the gland from a tubular to a lobular structural pattern or from a functionless phase to a state of secretory activity, when retention of secretion will cause dilatation and cysts, is the rule. The reverse changes are also observed.

1. Pathomorphology of the Lobules of the Gland

The changes of lobular structure, which frequently occur in benign dysplasias of the mammary gland and are essentially due to endocrine dysregu-

lation, are shown schematically in Fig. 24. Classification depends upon the mode of metaplasia of the lobuli.

1. *Regressive changes.* These are characterized by diminution of the size of the lobuli, associated with intralobular fibrosis of the mantle tissue and with broadening of the basal membrane. The epithelial parts up to the peripheral sectors of the lactiferous ducts atrophy. The terminal buds may be taken into

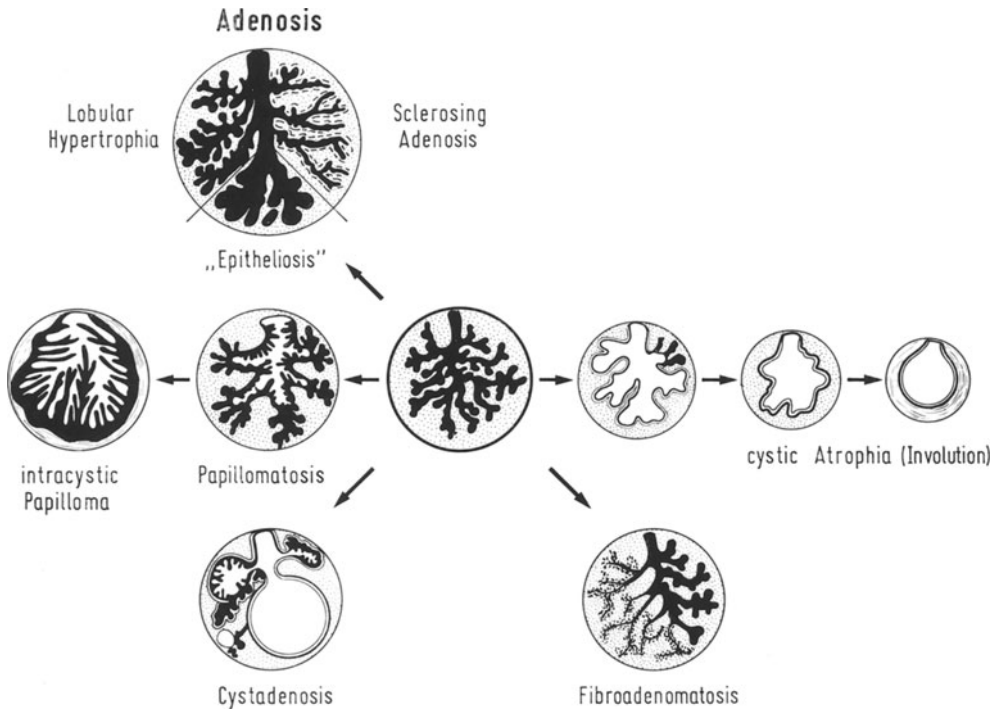


Fig. 24. Schematic representation of progressive and regressive changes in the glandular lobules of the mammary gland

the wall by increasing dilatation of the duct, and thus may then be transformed into a smooth-walled cyst. (Regarding delineation between dilatation and cyst, see BÖHMIG, 1952, 1964.) Type: senile atrophy, fibro-cystic mastopathy.

2. *Progressive changes.* This group is characterized by hyperplasia of the lobules with maintenance of their fundamental structure. The increase of epithelial components justifies the concept of adenosis, although differences in shape and order of magnitude should be allowed for.

a) *Lobular adenomatous hyperplasia* due to increase of regular or dilated adventitious proliferations. This is normal during pregnancy.

b) *Sclerosing adenosis* due to enlargement and confluence of lobules. Proliferation of myoepithelial cells and of the intralobular stroma whilst the glandular epithelium is maintained or atrophies (epimyothelial proliferation). (HAMPERL, 1940; FOOTE and STEWART, 1945; URBAN and ADAIR, 1949.)

c) *Epitheliotic or adenomatous intralobular proliferation of epithelium* with isomorphic solid, cribriform or papillomatous structures. Dilatation of terminal tubules and sectors of lobules, enlargement of lobular volume (BÖHMIG, 1964). DAWSON (1933) called this "epitheliosis" as against adenosis. Type: Schimmelbusch's adenosis; fibro-cystic mastopathy. Intermediate type between benignancy and malignancy. Delimitation towards lobular carcinoma (FOOTE and STEWART, 1941; NEWMAN, 1963, 1966; BÖHMIG, 1964; BÄSSLER, 1968).

3. *Papillary adenosis of the lobules and of the tubular system*. Commonly found in abnormal lobules. — Papillomas of the lactiferous ducts are found usually as circumscribed tumours in the large ducts near the mamilla (JONES, 1955).

Papillomatosis of the whole of the tubular system is unusual. Proliferation of the epithelium is then preceded by enlargement of large and small lactiferous ducts and is frequently accompanied by apocrine secretion. The ducts, which extend funnel-like, dissemble the lobular structure by inclusion of the terminal buds. Type: fibro-cystic mastopathy, papillary cystadenomas, macromastia.

4. *Combined metamorphosis of lobules with formation of cysts*. Commonly, proliferative and regressive changes coexist: metaplasia of lobules, dilatation of ducts and formation of cysts with apocrine secretion, also oedematous swelling of the mantle tissue. Type: mastodynia, fibro-cystic mastopathy.

5. *Proliferation of mantle tissue* with maintenance of the lobular structure or metaplasia (atrophy, proliferation), indicating hormonal stimulation. Type: fibroadenoma, angiomesenchymal macromastia types. Gynaecomastia.

2. Morphology and Function of the Intralobular or Mantle- and Circumlobular or Supporting Connective Tissue

Local proliferation of mesenchymal cells of the subepithelial connective tissue in the stage of budding between the 3rd—4th embryonal months is the first inductive reaction of the stroma to the proliferating epithelium. With increasing development of the gland the circumductular mesenchyma loosens, becomes transparent, rich in cells, and in the mammary gland of the newborn presents the essential portion of the stroma, surrounded by small terminal vesicles of collagenous fibres which lie only behind the fatty tissue and in the intermediary zone. When "witch's milk" is secreted, this portion of the mesenchyma is nearly completely replaced by the proliferating and extending glands, as happens later during pregnancy and lactation. When secretion of "witch's milk" ceases and the glands involute, the loose connective tissue is replaced by collagenous connective tissue, which in both sexes becomes that element of the gland that determines its shape (BÄSSLER, 1958a). At the beginning of sexual maturity the ducts and later the lobules are surrounded by a type of mesenchyma that is very similar to that present at the time of birth. BERKA (1911) distinguished this intralobular surrounding tissue from the rest of the interlobular supporting tissue of the mammary gland, which serves to shape and fix the body of the gland. The qualitative and quantitative

changes of the structure of the mammary gland under normal conditions are shown in the schematic illustration (Fig. 25).

Mantle tissue is a special and reactive type of mammary glandular mesenchyme, the development and regression of which mirrors the phases of hormonal activity. Its extensive vascularity and ability to produce cells are of importance for normal and abnormal interactions. Its multifarious pathogenetic properties may be summarized as follows:

1. Mantle tissue differentiates under the influence of mammotropic hormones, especially of oestrogens and, as Fig. 25 shows, is biomorphic. It is the

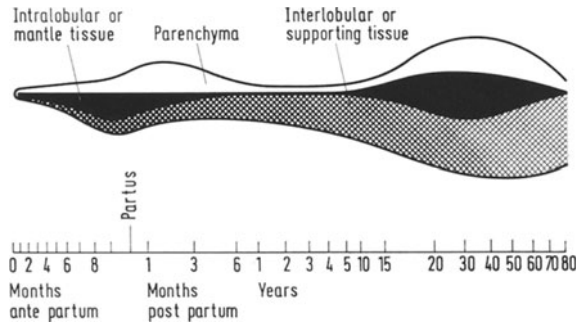


Fig. 25. Schematic representation of the quantitative and qualitative changes of the structure of the mammary gland under normal conditions

site of reaction for reversible oedematous swellings during the *menstrual cycle* (ROSENBERG, 1922; DIECKMANN, 1925; LITEN, 1926; LUCHSINGER and CENTANO, 1927; KUECKENS, 1929; TAYLOR, 1936; MASSHOFF, 1955) and a *zone of growth* (guide path according to DABELOW, 1933, 1934, 1941) for the proliferating epithelium.

On pathological stimulation mantle tissue appears characteristically as a circumtubular or lobular mesenchymal envelope in gynaecomastia, macromastia of puberty (virginal hypertrophy), mastodynia, fibro-cystic mastopathy, and in several types of macromastia (Fig. 26).

2. Mantle tissue is able to *produce blood cells* during the whole of life (cytogenic stroma of the mammary gland). In the newborn transient, but regular *foci of haemopoiesis* may be observed (GRUBER, 1921), and in erythroblastosis intensive and persistent haemeopoiesis may be present (BÄSSLER, 1958b). — In *haemoblastosis* haematopoiesis may arise anew at any age and cause extensive infiltrates (SEIFERT, 1952).

3. Mantle tissue as the site of *inflammatory* reactions develops cellular infiltrates in *circumductal* (periductal) *mastitis*, plasma and giant cells in *plasma cell mastitis* (ADAIR, 1933; CUTLER, 1933) and specific granulomas in miliary tuberculosis, for example.

4. Mantle tissue is the site of the development of *fibroadenomas*. These tumours are therefore thought to be hyperplasms of the mantle tissue and glandular structures. This is supported by the facts that they occur in the fertile phase of women and that they have a tendency to sclerosing during age.

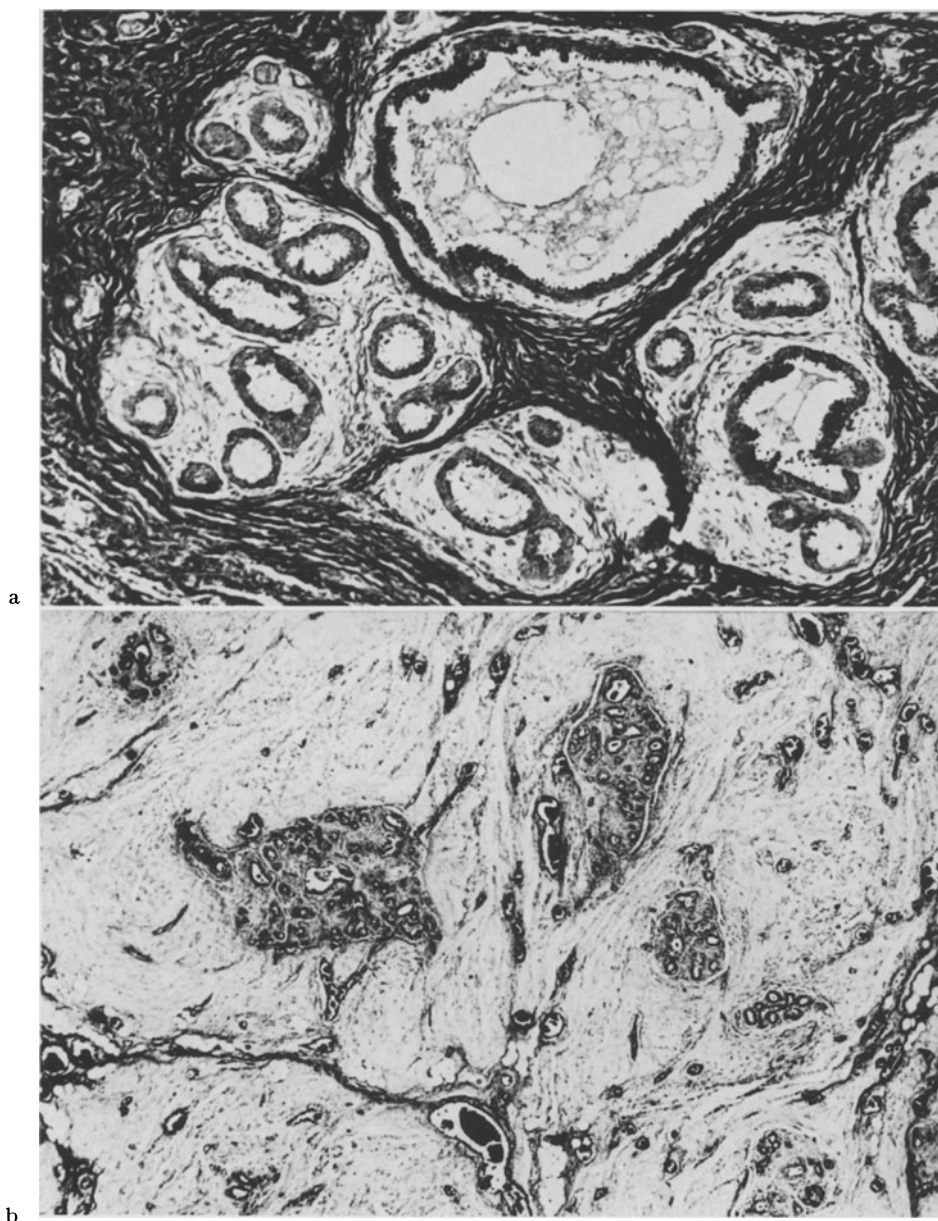


Fig. 26a and b. Two contrasting reaction types of the mesenchyma of the mammary gland. a Swelling and oedema of the mantle tissue during apocrine secretion of the glandular epithelium due to strong hormonal stimulation in macromastia. Formalin, paraffin, Azan., magnification $240\times$. b Oedematous loosening of supporting tissue with hyperemia and mantle tissue that is largely regular. Angiomesenchymal form of macromastia in Cushing's disease. Formalin, paraffin, HE, magnification $90\times$

Supporting tissue of the mammary gland. When the secretion of “witch’s milk” has ceased, collagenous connective tissue appears between the tubules as interstitium. It directly envelops the epithelial components of the mammary

gland and acts as supporting tissue until the onset of puberty. Before maturity the body of the gland consists mainly of a regular, dense stroma. Its isomorphism is subsequently maintained normally. With increasing age and in dysplasias focal and flat *hyalinoses* occur, which may be accompanied by *elastosis* (RIEDEL, 1925; BOHLE, 1951; VILLANI and ZANELLA, 1951) and atrophy of the parenchyma. The increase of supporting tissue is of particular importance in fibrocystic mastopathy. This increase is supposed to commence in the intralobular mantle tissue according to BÖHMIG (1964) and to observations by FOOTE and STEWART (1945) and COPELAND (1947).

Atrophy of the parenchyma and fibrosis are often accompanied by lipomatosis of the glandular body. My own observations have confirmed that even the stroma and residues of the intralobular connective tissue may be included in this, so that the epithelial portions of the lobuli are surrounded by fat cells only (stroma-free lobules).

Experimental work on fibrosing is based on the fact that the mammary gland of mature rodents has no mantle tissue in BERKA'S sense. Under the influence of sex hormones neutral and acid mucopolysaccharides are deposited in the circumtubular and lobular stroma (CHAIN and DUTHIE, 1940; DURAN-REYNALS, BUNTING and VAN WAGENEN, 1950; VITRY, 1953; OZZELLO and SPEER, 1958). The retention and absorption of residual secretion from proliferating glands is the precondition of fibrosing. This last is stronger after lactation and galactostasis (SCHRIEVER, 1968). Reactions of the mesenchyme analogous to fibro-cystic mastopathy have not been observed, although after treatment of rats with oestrogen fibroadenomatous structures have occasionally been found in the circumtubular mesenchyme.

3. Aetiology and Pathogenesis of Benign Dysplasias

Structural changes of the mammary gland are due, on the whole, either to changes of the mechanisms of hormonal regulation or to tissue reactions being inadequate. The multitude of morphological and endocrinological symptoms makes classification difficult from a pathogenetic point of view, but to three large groups may be distinguished:

1. *Dysplasias and functional disorders due to changes of the quantity of mammotropic hormones.*

Accessory endogenous or exogenous compounds may stimulate development, secretion, and growth. They may cause hyperplasia (macromastia) of the mammary gland, when usually special tissue patterns are being developed.

a) *Secretion of "witch's milk"* is due to the joint action of hormones transferred through the placenta (choriogonadotropic hormones, follicular hormone) and of the mammotropin of the child (PHILIPP, 1938; LYONS, 1938; MERZ, 1946; DICZFALUSY, TILLINGER and WESTMAN, 1957).

b) *Macromastia of puberty* (virginal hypertrophy) at the beginning of sexual maturity through the influence of oestrogen (GESCHICKTER, 1948; BÄSSLER, 1966). Gynaecomastia of puberty [mastitis in adolescence, "early ripening"]

(GESCHICKTER, 1948)]. This is usually transient, uni- or bilateral at the beginning of puberty. Morphologically corresponds to virginal hypertrophy.

c) *Gynaecomastia*, a polyaetiological syndrome due to increased growth impulses caused by hormones. Types: usually tubular gynaecomastia; more rarely true lobular gynaecomastia. Causes: endogenous or exogenous action of oestrogen, rarely other hormones or drugs (BREDT, 1932; KARSNER, 1946; NORDMANN, 1948; BOEMKE and BIRKLE, 1949; OVERZIER, 1949; KUNERT, 1951; SCHNURBUSCH, 1951; TREVES, 1958; BÄSSLER and SCHÄFER, 1968, 1969).

d) *Macromastia* due to hormone-active tumours of the ovary (granulosa-cell tumour: HABBE, 1931; carcinoma of the ovary: MÜLLERHEIM, 1928; together with disgerminoma and acromegaly: BÄSSLER, 1966), after administration of digitalis (CALOV and WHYTE, 1954; BLOCH, 1961); in endocrine disorders (CUSHING's disease: BÄSSLER, 1966).

e) *Hypoplasia and atrophy* in lack or deficiency of hormones.

f) *Atypical and papillary proliferation of epithelium* in harmless fibroadenomas of the mammary gland following the use of *oral contraceptives for several months* (GOLDENBERG, WIEGENSTEIN and MOTTET, 1968).

2. *Dysplasias due to changes of hormonal equilibrium.*

Preponderance of oestrogen and relative diminution of progesterone is a frequent cause of local and diffused disorders of the mammary gland.

a) *Mastodynia* (mazoplasia, CHEATLE and CUTLER, 1931; simple fibroadenomatosis, SEMB, 1928): Painful circumscribed swellings, increased consistency, usually in the upper outer quadrant, age 25—40 years. Menstrual cycle is shortened (GESCHICKTER, 1948; CUTLER, 1961). Irregular structure of the lobules, small cysts, multilayered epithelium, secretion, oedematous swelling of mantle tissue. Pregnan diol excretion in urine is only a third of normal, oestrogen remains unchanged (GESCHICKTER, 1948).

b) *Adenosis* (papillary cystadenoma, SCHIMMELBUSCH, 1892). Occurs at the ages of between 35 and 45 years, uni- or bilateral, prefers upper outer quadrant and middle of gland. Menstrual cycle is irregular. Microscopically strong proliferation of epithelium is seen in terminal tubuli with intracanalicular adenomas and papillomas and formation of cysts. Condition is to be understood as advanced stage of mastodynia. Hormone excretion as in mastodynia. According to GESCHICKTER (1948) it is due to relative hyperoestrogenism.

c) *Chronic cystic mastopathy*. (Morphology and symptomatology, KONJETZNY, 1942; GESCHICKTER, 1948; FRANTZ a.o., 1951; KONJETZNY, 1954; CUTLER, 1961; BÖHMIG, 1964, references, MÖBIUS a. NIZZE, 1966). Occurs between 40—50 years, prefers the upper and outer quadrant. — Excretion of pregnan diol greatly diminished, that of oestrogen sometimes greatly increased (GESCHICKTER, 1941, 1948). Numerous old and new investigations about aetiology and pathogenesis have shown that fibrocystic mastopathy is caused by persistent preponderance of oestrogen with relative diminution of progesterone. Although generally accepted, this concept has also been opposed (TAYLOR, 1936). It leaves a good many questions open, mainly those concerning quantity and quality of the pathogenetic factors.

The aetiological importance of hyperoestrogenism for fibrocystic mastopathy has been underscored by contrasting fibro-cystic mastopathy with the results of experimental research into hormonal action (BURROWS, 1935/36; HOFFMANN, 1939; TAYLOR and WALTMAN, 1940; INGLEBY, 1942; AVERBACH, 1956) and the happenings after administration of oestrogen for months, as described by GRUMBRECHT (1941) and EISEN (1942).

3. *Dysplasias as inadequate reactions.*

Physiological stimulation triggers off excess production. Example: macromastia of pregnancy.

4. Galactorrhoea in the Human Mammary Gland

Abnormal secretion is not only a guiding sign of disorders of the mammary gland, but is frequently due to increased formation of lactogenous hormones by tumours of the pituitary or to drugs. Apart from the sanguinous secretion of the mammary gland during excretion of "witch's milk", at the time of menstruation and in the case of tumours (SCHULTZ, 1933), only those kinds of galactorrhoea will be discussed where a *milk-like fluid is excreted from the mamilla outside the period of normal lactation*, in view of the importance of prolactin for secretion. Only this should be called galactorrhoea. It must be distinguished from common discontinuous excretions of the human mammary gland that accompany well-known syndromes and disorders of this organ and that may cause retention of secretion and lead to formation of cysts.

Causes and types of galactorrhoea:

1. *Chiari-Frommel syndrome.* The authors (1855 and 1881) called this a *post-partum abnormal lactation in post-partum amenorrhoea*, hypogenitalism, psychoses, and malnutrition. The review by DANOWSKI (1962) contains 13 case reports, four of which have been taken from a study by FORBES, HENNEMAN, GRISWOLD, and ALBRIGHT (1954). — The criticism may be voiced that intermediary forms of late lactation cannot be properly delineated from this syndrome, because morphological and endocrinological studies are lacking.

2. *Ahumada-del Castillo syndrome (1932).* Characterized by the triad: *galactorrhoea with amenorrhoea in non-pregnant women, lowered or lacking excretion of gonadotropin*, and signs of ovarian insufficiency. No pituitary tumour. In a subsequent study by ARGONZ and DEL CASTILLO (1953) and another by FORBES, HENNEMAN, GRISWOLD, and ALBRIGHT (1951, 1954) the assumption was made that the lowering of the blood oestrogen level caused an increase of lactogenic hormone and triggered off galactorrhoea. The acidophil cells of the adenohipophysis were proposed as site of production of the lactogenic hormone. Latest immunohistochemic investigations by KRACHT, HACHMEISTER, BREUSTEDT, and ZIMMERMANN (1967) have shown that prolactin and STH are produced by the acidophilic cell complex of the pituitary, although plurihormonal performance of individual cell types cannot be excluded. — Obesity, hirsutism, and hypoplasia of the genitals have been described as part of the syndrome. Galactorrhoea may persist for years (DANOWSKI, 1962). —

Observations of five cases with Ahumada-del Castillo syndrome by SPELLACY, CARLSON, and SCHADE (1968) showed normal values of growth hormone in blood. Symptoms presented that indicated a hypothalamic-hypophyseal disorder as cause of the galactorrhoea. — Whereas the association of amenorrhoea and galactorrhoea is well recognized, recently NYIRJESY (1968) has described *galactorrhoea in normal ovulatory women*.

3. *Forbes-Albright syndrome. Galactorrhoea in tumours of the pituitary and brain disorders.*

When the acidophilic cells of the adenohypophysis contain prolactin, it may be expected that adenomas of these cells may produce increased secretion. Galactorrhoea has been found in 4% of cases of *acromegaly* (LABHART, 1959; NEIMEIER, HAUSER, KELLER, LABHART, WENNER, STAMPFLI, 1959). Postpartum galactorrhoea in acromegaly is also called *Chiari-Frommel syndrome*. — In *Cushing's disease* abnormal secretion of the mammary gland is observed by SCHALTENBRAND (1951) and in a new case report with abnormal lactation, chromophobe adenoma of the pituitary and a marked elevated secretion rate of urinary steroids and cortisol by MAHESH, DALLA PRIA and GREENBLATT (1969). Finally, *chromophobic adenomas of the pituitary* have been thought to be causes of galactorrhoea. KRAUS (1935) reported two cases, FORBES, HENNE-MAN, GRISWOLD and ALBRIGHT (1954) three cases, SUCHENWIRTH and BUES (1961) two cases, in which *galactorrhoea was the earliest endocrinological sign* of a tumour of the pituitary and where in one case it was accompanied by urinary excretion of prolactin corresponding to late pregnancy. For the aetiological clarification of galactorrhoea radiological and clinico-chemical examinations about the size of the sella and the function of the pituitary are absolutely necessary.

4. *Galactorrhoea accompanied by disorders of thyroid function. Van Wyk-Grumbach syndrome: Galactorrhoea in hypothyroidism and premature menstruation. Zondek-Bromberg-Rozin syndrome: Galactorrhoea in hyperthyroidism.* — An unusual coincidence of post-operative hypothyroidism, deficient function of the epithelial bodies, galactorrhoea, and undisturbed menstruation has been described by CLARK, SHAPIRO and MONROE (1956).

5. *Further causes of galactorrhoea.*

Disorders of the diencephalon in post-encephalitic Parkinsonism and administration of reserpine and chlorpromazine have been held responsible for galactorrhoea in rare cases (DANOWSKI, 1962). Individual cases of galactorrhoea in men may be due to angiosarcoma of the pituitary (HAENEL, 1928), be related to gynaecomastia (ZUM BUSCH, 1927; ALBORES CULEBRO, 1946; McCULLAGH, ALIVISATOS, and SCHAFFENBURG, 1956), occur in tumours of the adrenals (BITTORF, 1919), tumours of the pineal gland (OESTREICH and SLAWYK, 1899) and chorion epithelioma (COOKE, 1915). *A familial nonpuerperal galactorrhoea* in three sisters is the first reported instance of galactorrhoea occurring either spontaneously or after oral contraceptive therapy (WIDER, MARSHALL and Ross, 1969).

Further observations of *galactorrhoea subsequent to contraceptive hormones* are described by GREGG (1966), ROSEN and GAHRES (1967) and SCHACHNER (1966).

Galactorrhoea after castration and lowered excretion of FSH is studied by JAKOBOVITS (1960).

In a study of 5 cases of non-acromegalic persistent lactation by LEVINE, BERGENSTAL and THOMAS (1962) the analysis of milk secreted by 3 of these women revealed a consistently low lactose and a high protein content. — *Breast biopsies* demonstrated a pattern similar to subinvolution of a previously lactating mammary gland.— Secretion of milk due to tactile suckling stimulus of the nipple of men has been observed, so that fathers were able to suckle their children (HUMBOLDT, *Journey into the Equinoctial Regions*, 1889).

Much earlier it had been written: "Men who have a little milk may produce it in large quantities as soon as their breasts are suckled!" (ARISTOTELES, *Historia animalium*, Lib. III, c. 20).

I wish to thank Miss S. WALTER and Mrs. HANENBERGER for technical assistance and photographic work and Präparator Mr. W. MEYER for drawings and illustrations.

References

- ADAIR, F. E.: Plasma cell mastitis. *Arch. Surg.* **26**, 735—749 (1933).
- AHRÉN, K.: (a) The effect of various doses of oestrone and progesterone on mammary glands of castrated hypophysectomized rats injected with insulin. *Acta endocr. (Kbh.)* **30**, 435—458 (1959).
- (b) Mammary gland development in hypophysectomized rats injected with anterior pituitary hormones and testosterone. *Acta endocr. (Kbh.)* **31**, 228—240 (1959).
- ETIENNE, M.: Stimulation of mammary glands in hypophysectomized male rats treated with ovarian hormones and insulin. *Acta endocr. (Kbh.)* **28**, 89—102 (1958).
- — The effect of testosterone alone and combined with insulin on the mammary glands of castrated and hypophysectomized rats. *Acta endocr. (Kbh.)* **30**, 109—136 (1959).
- HAMBERGER, L.: Direct action of testosterone propionate on the rat mammary gland. *Acta endocr. (Kbh.)* **40**, 265—276 (1962).
- JACOBSON, D.: Mammary gland growth in hypophysectomized rats injected with ovarian hormones and insulin. *Acta physiol. scand.* **37**, 190—203 (1956).
- — The action of cortison on the mammary glands of rats under various states of hormonal imbalance. *Acta physiol. scand.* **40**, 254—274 (1957).
- AHUMADA, I. C., DEL CASTILLO, E. B.: Amenorrea galactorrea. *Biol. Soc. obstet. y Ginec.* **11**, 64—72 (1932).
- ALBORG CULEBRO, C.: Un caso de ginecomastia o andro galactozemia. *Toréon méd.* **1**, 80 (1946).
- ALTMANN, H. W.: Der Zellersatz, insbesondere an den parenchymatösen Organen. *Verh. dtsh. Ges. Path.* **50**, 15—51 (1966).
- ANDERSON, R. R., BROOKKRESON, A. D., TURNER, C. W.: Experimental growth of mammary gland in male and female mice. *Proc. Soc. exp. Biol. (N. Y.)* **106**, 567—570 (1961).
- ARGONZ, J., DEL CASTILLO, E. B.: A syndrome characterized by estrogenic insufficiency, galactorrhea and decreased urinary gonadotropin. *J. clin. Endocr.* **13**, 79—87 (1953).

- ARHELGER, ST. W., HUSELY, R. A.: Estrogen-Androgen antagonism: Histology of mammary glands and vaginal grafts of male mice receiving estrogens. *Proc. Soc. exp. Biol. (N. Y.)* **76**, 811—817 (1951).
- ARISTOTELES: *Historia animalium*. Lit. III. c. 20. Zit. nach Wenner.
- ASBOE-HANSEN, G.: Hormonal effects on connective tissue. *Physiol. Rev. (Baltimore)* **38**, 446—462 (1958).
- Endocrine control of connective tissue. *Amer. J. Med.* **26**, 470—484 (1959).
- ASTWOOD, E. B., GESCHICKTER, C. F.: Changes in mammary gland of rat produced by various glandular preparations. *Arch. Surg.* **36**, 672—697 (1938).
- — RAUSCH, E. O.: Development of the mammary gland of the rat. A study of normal, experimental and pathologic changes and their endocrine relationships. *Amer. J. Anat.* **61**, 373—405 (1937).
- AVERBACH, M. M.: Über die Histogenese der Mastopathien und Fibroadenome der Mammae. *Arch. Path. (Moskau)* **18**, H. 3, 65—71 (1956) [Russisch]. *Ref. Ber. allg. spez. Path.* **34**, 186 (1957).
- AVERILL, R. L. W.: The hypothalamus and lactation. *Brit. med. Bull.* **22**, 261—265 (1966).
- RAY, E. W., LYONS, W. R.: Maintenance of pregnancy in hypophysectomized rats with placental implants. *Proc. Soc. exp. Biol. (N. Y.)* **75**, 3—6 (1950).
- BÄSSLER, R.: Zur Pathologie der kindlichen Brustdrüsen. *Beitr. path. Anat.* **118**, 390—406 (1957).
- Beiträge zur Morphologie der kindlichen Brustdrüse. *Frankfurt. Z. Path.* **69**, 37—52 (1958).
- Elektronenmikroskopische Beobachtungen bei experimenteller Milchstauung. *Frankfurt. Z. Path.* **71**, 398—422 (1961).
- Formen der Makromastie. *Beitr. path. Anat.* **133**, 430—460 (1966).
- Neuere Aspekte der normalen und pathologischen Feinstruktur der Mamma. *Hippokrates (Stuttg.)* **39**, 237—244 (1968).
- Das sogenannte lobuläre Carcinom der Mamma. *Dtsch. med. Wschr.* **94**, 108—113 (1968).
- BRETHFELD, V.: Enzymhistochemische Studien an der Milchdrüse. Gravidität-Laktation, Involution und experimentelle Stauung mit besonderer Berücksichtigung myoepithelialer Zellen. *Histochemie* **15**, 270—286 (1968).
- FLÖRCHINGER, J.: (a) Histometrische Studien an der laktierenden Milchdrüse. I. Mitteilung: Lactation und physiologische Involution. *Arch. Gynäk.* **203**, 366—399 (1966).
- — (b) Histometrische Studien an der lactierenden Milchdrüse. II. Mitteilung: Experimentelle Milchstauung und vermehrtes Flüssigkeitsangebot durch Peristoninfusionen. *Arch. Gynäk.* **203**, 400—422 (1966).
- FORSSMANN, W.: Experimenteller Strukturwandel der Drüsenzelle durch Hormonwirkung. *Verh. dtsch. Ges. Path.* **48**, 240—244 (1964).
- PÄEK, S.: Histochemisches Enzymmuster der Mamma unter dem experimentellen Einfluß von Geschlechtshormonen. *Histochemie* **13**, 29—44 (1968).
- SCHÄFER, A.: Elektronenmikroskopische und experimentelle Untersuchungen zur Morphologie der Gynäkomastie. *Verh. dtsch. Ges. Path.* **52**, 491—498 (1968).
- — (a) Elektronenmikroskopische Cytomorphologie der Gynäkomastie. *Virchows Arch. Abt. A Path Anat.* **348**, 356—373 (1969).
- — (b) Elektronenmikroskopische Cytomorphologie der männlichen Brustdrüse. *Z. Zellforsch.* **101**, 355—366 (1969).
- — PÄEK, S.: Elektronenmikroskopische und histochemische Untersuchungen zur Morphologie und Funktion myoepithelialer Zellen. *Verh. dtsch. Ges. Path.* **51**, 301—307 (1967).

- BÄSSLER, R., SCHULZE, G., SCHRIEVER, D.: Histochemische Untersuchungen am Bindegewebe der hormonal stimulierten Mamma. Experimentelle Beiträge zur Pathogenese von Fibrosierungen in der Brustdrüse. Beitr. path. Anat. (in press).
- BALDWIN, R. L., MARTIN, R. J.: Protein and nuclein acid synthesis in rat mammary glands during early lactation. *Endocrinology* **82**, 1209—1216 (1968).
- BALINSKY, B. I.: (a) On the prenatal growth of the mammary gland rudiment in the mouse. *J. Anat. (Lond.)* **84**, 227—235 (1950).
- (b) On the developmental processes in mammary glands and other epidermal structures. *Trans. roy. Soc. Edinb.* **62**, 1—31 (1956).
- BANERJEE, M. R., WALKER, R. J.: Variable duration of DNA-synthesis in mammary gland cells during pregnancy and lactation of C₃H/HE mouse. *J. Cell Physiol.* **69**, 133—142 (1967).
- BARDIN, C. W., LIEBELT, A. G., LIEBELT, R. A.: The direct effect of pituitary isografts on mammary gland development in the mouse. *Proc. Soc. exp. Biol. (N. Y.)* **110**, 716—718 (1962).
- — — Effect of hypophysial isografts on the mammary glands of intact and hypophysectomized mice. *Endocrinology* **74**, 586—592 (1964).
- BARGMANN, W., FLEISCHHAUER, K., KNOOP, A.: Über die Morphologie der Milchsekretion. II. Zugleich eine Kritik am Schema der Sekretionsmorphologie. *Z. Zellforsch.* **53**, 545—568 (1961).
- BEATO, M., DIENSTBACH, F.: Effect of estrogens and gestagens on the duration of DNA synthesis in the genital tract of ovariectomized mice. *Virchows Arch. Abt. B. Zellpath.* **1**, 197—200 (1968).
- BENGTSSON, B., NORGRÉN, A.: Interactions of oestrone and testosterone on mammary glands of male rabbit. *Acta endocr. (Kbh.)* **36**, 141—156 (1961).
- BENSON, G. K., COWIE, A. T., COX, C. P., FLUX, D. S., FOLLEY, S. J.: Studies on the hormonal induction of mammary growth and lactation in the goat. II. Functional and morphological studies of hormonally developed udders with special reference to the effect of "triggering" doses of oestrogen. *J. Endocr.* **13**, 46—58 (1955).
- — — FOLLEY, S. J., HOSKING, Z. D.: Relative efficiency of hexoestrol and progesterone as oily solutions and as crystalline suspensions in inducing mammary growth and lactation in early and late ovariectomized goats. *J. Endocr.* **31**, 157—164 (1965).
- — — GOLDZWEIG, S. A.: Effects of oestrone and progesterone on mammary development in guinea-pig. *J. Endocr.* **15**, 126—144 (1957).
- — FOLLEY, S. J., TINDAL, J. S.: Recent developments in endocrine studies on mammary growth and lactation. In: *Recent progress in the endocrinology of reproduction* (C. W. Lloyd, ed.), p. 457—490. New York: Academic Press 1959.
- FOLLEY, S. J.: (a) Oxytocin as stimulator for the release of prolactin from the anterior pituitary. *Nature (Lond.)* **177**, 700 (1956).
- — (b) Retardation of mammary involution in the rat by oxytocin. *J. Endocr.* **14**, 42 (1957).
- — (c) The effect of oxytocin on mammary gland involution in the rat. *J. Endocr.* **16**, 189—201 (1957).
- BERDE, B.: *Recent progress in oxytocin research*. Amer. Lect. Series. Springfield, Ill.: C. C. Thomas Publ. 1959.
- CERLETTI, A.: Über die Wirkung pharmakologischer Oxytocindosen auf die Milchdrüse. *Acta endocr. (Kbh.)* **34**, 543—557 (1960).
- BERGER, H.: Beitrag zur elektronenoptischen Zelldifferenzierung des soliden Mammacarcinoms und der Mastopathia cystica des Menschen. *Z. Krebsforsch.* **66**, 73—86 (1964).
- BERK, F.: Beitrag zur Kenntnis der ersten Anlage der menschlichen Brustdrüse. *Med. Inaug.-Diss. Greifswald* 1913.

- BERKA, F.: Die Brustdrüse verschiedener Altersstufen und während der Schwangerschaft. Frankfurt. Z. Path. **8**, 203—256 (1911).
- BERSWORDT-WALLRABE, R. v.: (a) Die Hemmung der Galaktopoese der Albinomaus durch Dienöstroldiacetat und ihre Auswirkungen auf das inkretorische System. Arch. Gynäk. **190**, 549—618 (1958).
- (b) Versuch einer theoretischen Erklärung der Hemmung der Galaktopoese der Albinomaus durch Dienöstroldiacetat. Arch. Gynäk. **190**, 619—637 (1958).
- TURNER, C. W.: (a) Mammogenesis in ovary-thyro-parathyroidectomized rats. Proc. Soc. exp. Biol. (N. Y.) **103**, 536—537 (1960).
- — (b) Dihydrotachysterol (AT 10) and mammogenesis in ovary-thyro-parathyroidectomized rats. Proc. Soc. exp. Biol. (N. Y.) **104**, 599—602 (1960).
- BIEDERMANN, K.: Das Verhalten des Genitalapparates weiblicher Ratten bei langdauernder Follikelhormonzufuhr. Arch. Gynäk. **167**, 465—476 (1938).
- BITTORF, A.: Nebennierentumor und Geschlechtsdrüsenausfall beim Manne. Berl. klin. Wschr. **56**, 776 (1919).
- BLOCH, K.: Zur Pathogenese der Mammahypertrophie bei der Digitalisapplikation. Z. Kreisl.-Forsch. **50**, 591—595 (1961).
- BÖHMIG, R.: (a) Die Epithelproliferationen bei der Mastopathia fibrosa cystica. Zbl. allg. Path. path. Anat. **89**, 297—313 (1952).
- Mastopathia fibrosa cystica. Ergebn. allg. Path. path. Anat. **45**, 39—116 (1964).
- BOEMKE, F., BIRKLE, K.: Zur Ätiologie der Fibrosis mammae virilis. Klin. Wschr. **1949**, 93—96.
- BOHLE, A.: Beitrag zur Frage der Elastica-Vermehrung in Mammatumoren. Frankfurt. Z. Path. **62**, 167—183 (1951).
- BOTTOMLEY, A. C., FOLLEY, S. J.: Effect of androgenic substances on growth of teat and mammary gland in immature male guinea pig. Proc. roy. Soc., London, Biol. Sci. **126**, 224—241 (1939).
- BRADLEY, T. R., COWIE, A. T.: (a) The effects of hypophysectomy on the in vitro metabolism of mammary gland slices from lactating rats. J. Endocr. **14**, 8—15 (1956).
- CLARK, P. M.: (b) The response of rabbit mammary glands to locally administered prolactin. J. Endocr. **14**, 28—36 (1956).
- BRANDES, D., ANTON, E., BARNARD, S.: Lysosomes and cellular regressive changes in rat mammary gland involution. Lab. Invest. **20**, 465—471 (1969).
- BRANDT, G.: Die experimentelle Pathomorphogenese intramammärer Verkalkungen. Inaug.-Diss. Mainz, 1968.
- BÄSSLER, R.: Calciphylaktische Reaktionen der Mamma. Vortrag z. Tagg der nordwestdeutschen Pathologen, Bielefeld, 11.—13. Okt. 1968. Zbl. allg. Path. path. Anat. (in press).
- — Pathomorphogenese experimenteller Verkalkungen in der weiblichen Brustdrüse. Virchows Arch. Abt. A Path. Anat. **348**, 139—154 (1969).
- BREDT, H.: Über Wesen und Formen der Gynäkomastie. Z. menschl. Vererb.- u. Konstit.-Lehre **17**, 29—54 (1932).
- BRESCIANI, F.: DNA-synthesis in alveolar cells of the mammary gland: Acceleration by ovarian hormones. Science **146**, 653—655 (1964).
- Effect of ovarian hormones on duration of DNA synthesis in cells of the C₃H mouse mammary gland. Exp. Cell Res. **38**, 13—32 (1965).
- BROMAN, J.: Die Entwicklung des Menschen vor der Geburt. München: J. F. Bergmann 1927.
- BROUHA, H.: Recherches sur les diverses phases du developpement et de l'activité de la mamelle. Arch. Biol. (Liège) **21**, 459—605 (1905).
- BROWNING, H. C., WHITE, W. D.: Local stimulation of mammary glands by pituitary or ovarian grafts in the mouse. Tex. Rep. Biol. Med. **23**, 26—37 (1965).

- BROWNING, H. C., WHITE, W. D., GIBBS, W.: Comparative stimulation of mammary gland by pituitary isografts with or without ovarian transplants. *Tex. Rep. Biol. Med.*, **22**, No. 1, Spring (1964).
- BUNTING, H.: The distribution of acid mucopolysaccharides in the mammalian tissues as revealed by histochemical methods. *Ann. N. Y. Acad. Sci.* **52**, 977—982 (1950).
- BURROWS, H.: Pathological changes induced in the mamma by oestrogenic compounds. *Brit. J. Surg.* **23**, 191—213 (1935/36).
- BUSCH, J. P. ZUM: Gynäkomastie bei Hypernephrom. *Dtsch. med. Wschr.* **53**, 323 (1927).
- BUSCH, W., MERKER, H.-J.: Elektronenmikroskopische Untersuchungen an menschlichen Mammacarcinomen. *Virchows Arch. Abt. A Path. Anat.* **344**, 356—371 (1968).
- CALOV, W. L., WHYTE, H. M.: Oedema and mammary hypertrophia: Toxic effect of digitalis leaf. *Med. J. Aust.* **41**, 556—557 (1954).
- CANIVENC, R., MAYER, G.: Nature du facteur lutéotrophique de placenta de rat. *C. R. Soc. Biol. (Paris)* **147**, 1067—1070 (1953).
- CASPERSSON, T.: Cell growth and cell function. New York 1945.
- CATCHPOLE, H. R., LYONS, W. R.: The lactation hormone of the hypophysis. *Anat. Rec.* **55**, 48—49 (1933).
- — REGAN, W. M.: Induction of lactation in heifers with the hypophyseal lactogenic hormone. *Proc. Soc. exp. Biol. (N. Y.)* **31**, 301—303 (1933).
- CHAIN, E., DUTHIE, E. S.: Identity of hyaluronidase and spreading factor. *Brit. J. exp. Path.* **21**, 324—338 (1940).
- CHALKLEY, H. W.: Method for the quantitative morphologic analysis of tissues. *J. nat. Cancer Inst.* **4**, 47—53 (1943).
- CHAMBERLIN, T. L., GARDNER, W. U., ALLEN, E.: Local responses of the sexual skin and mammary glands monkeys to cutaneous applications of estrogen. *Endocrinology* **28**, 753—757 (1941).
- CHAMORRO, A.: Action de la progesteron seule sur la glande mammaire. *C. R. Soc. Biol. (Paris)* **138**, 453—456 (1944).
- CHAUDHURY, R. R., WALKER, J. M.: Rate of disappearance of injected oxytocin from the blood. *J. Physiol. (Lond.)* **138**, 50—61 (1957).
- CHEATLE, G. L., CUTLER, M.: Tumors of the breast. London: Ed. Arnold & Co. 1931
- CHEN, TH. T., JOHNSON, R. E., LYONS, W. R., LI, C. H., COLE, D. R.: Hormonally induced mammary growth and lactation in the absence of the thyroid. *Endocrinology* **57**, 153—174 (1955).
- CHENTSOV, Y., CHENTSOV, S.: Electron microscopy of rat mammary glands on lactation, hormonal stimulation and in the case of postradiation fibroadenoma. *Acta Un. int. Cancr.* **20**, 1377—1378 (1964).
- CHIQUOINE, A. D.: The identification and electron microscopy of myoepithelial cells in the harderian gland. *Anat. Rec.* **132**, 569—584 (1958).
- CLARK, B. G., SHAPIRO, S., MONROE, R. G.: Postthyroidectomie, hypothyroidism, hypoparathyroidism, exophthalmos and galactorrhoea with normal menstruation: metabolic response to propened. *J. clin. Endocr.* **16**, 1245—1251 (1956).
- CLIFTON, K. H., FURTH, J.: Ducto-alveolar growth in mammary glands of adrenalectomized male rats bearing mammatropic pituitary tumors. *Endocrinology* **66**, 893—897 (1960).
- COLE, R., HOPKINS, T. R.: Maintenance of the mammary gland in hypophysectomized — oophorectomized rats by injection of protein. *Endocrinology* **71**, 395—398 (1962).
- CONSOLANDI, G.: La problema de cancro gelatinoso della mamella. *Lav. Ist. Anat. Univ. Perugia* **6**, 35—76, 119—155 (1947).

- COOKE, J. V.: Chorio-epithelioma of the testicle. Bull.-Johns Hopk. Hosp. **26**, 215—221 (1915).
- COPELAND, M. M.: New aspects of benign tumours of the breast. Arch. Surg. **55**, 590—621 (1947).
- CORNER, G. W.: The hormonal control of lactation. Amer. J. Physiol. **95**, 43—55 (1930).
- COWIE, A. T.: The relative growth of the mammary gland in normal, gonadectomized and adrenalectomized rats. J. Endocr. **6**, 145—147 (1949).
- Recent studies on the endocrine control of the mammary development and milk secretion. Colloq. int. Cent. nat. Rech. sci., No. **32**, p. 45—57 (1951).
- The hormonal control of milk secretion. In: Milk: The mammary gland and its secretion, ed. by S. K. Kon and A. T. Cowie, vol. I. New York and London: Academic Press 1961.
- FOLLEY, S. J.: Parathyroidectomy and lactation in the rat. Nature (Lond.) **156**, 719—721 (1945).
- — The mammary gland and lactation. In: Sex and internal secretions, ed. by W. C. Young and G. W. Corner, vol. II, p. 590—642. Baltimore: The Williams & Wilkins Co. 1961.
- — CROSS, B. A., HARRIS, G. W., JACOBSON, D., RICHARDSON, K. C.: Terminology for use in lactational physiology. Nature (Lond.) **168**, 421 (1951).
- — MALPRESS, F. H., RICHARDSON, K. C.: Studies on the hormonal induction of mammary growth and lactation in the goat. J. Endocr. **8**, 64—88 (1952).
- LYONS, W. R.: Mammogenesis and lactogenesis in hypophysectomized, ovariectomized, adrenalectomized rats. J. Endocr. **19**, 29—32 (1959).
- TINDAL, J. S., YOKOYAMA, A.: The induction of mammary growth in the hypophysectomized goat. J. Endocr. **34**, 185—195 (1966).
- CURTISS, C.: Factors influencing lobulo-alveolar development and mammary secretion in the rat. Endocrinology **45**, 284—295 (1949).
- CUTLER, M.: Benign lesion of the female breast simulating cancer. J. Amer. med. Ass. **101**, 1217—1222 (1933).
- Tumors of the breast. Philadelphia: Lippincott 1961.
- DAANE, TH. A., LYONS, W. R.: Effect of estrone, progesterone and pituitary mammotropin on the mammary glands of castrated C₃H male mice. Endocrinology **55**, 191—199 (1954).
- DABELOW, A.: Der Entfaltungsmechanismus der Mamma. I. Das Verhalten von Gefäßsystem und Drüsenbaum während der Laktationsentwicklung der Mamma bei Maus, Ratte, Meerschweinchen und Kaninchen. Morph. Jb. **73**, 69—99 (1934).
- Vergleichende Untersuchungen zur Entwicklung einiger Drüsen, ihrer Gefäßbäume und ihrem Verhalten zum umgebenden Gewebe. Verh. anat. Ges. (Jena), p. 165—188 (1934).
- Der Entfaltungsmechanismus der Mamma. II. Die postnatale Entwicklung der menschlichen Milchdrüse und ihre Korrelationen. Morph. Jb. **85**, 361—416 (1941).
- Die Milchdrüse. In: Handbuch der mikroskopischen Anatomie des Menschen, hrsg. von W. v. Moellendorff u. W. Bargmann, Haut- und Sinnesorgane, Ergänz. zu Bd. 3/1, S. 277ff. Berlin-Göttingen-Heidelberg: Springer 1957.
- DAMM, H. C., TURNER, C. W.: Effects of anterior pituitary preparations on mammary gland growth in mouse. Prox. Soc. exp. Biol. (N. Y.) **107**, 893—895 (1961).
- DANOWSKI, T. S.: Clinical endocrinology, vol. I. Baltimore: The Williams & Wilkins Comp. 1962.
- DAWSON, E. K.: Carcinoma in the mammary lobule and its origin. Edinb. med. J. **40**, 57—60 (1933).
- DELLWEG, H.: Antibiotica und Hormone — ihre Wirkung auf die Biosynthese von Nucleinsäuren und Proteinen. In: Molekularbiologie, hrsg. von T. WIELAND und G. PFLEIDERER, S. 83—94. Frankfurt/M.: Umschau Verlag 1967.

- DEMPSEY, E. A., BUNTING, H., WISLOCKI, G. B.: Observations on the chemical cytology of the mammary gland. *Amer. J. Anat.* **81**, 309—341 (1947).
- DESCLIN, L.: (a) L'ocytocine peut-elle déclencher la libération de lutéotrophine hypophysaire chez la rat? *C. R. Soc. Biol. (Paris)* **150**, 1489—1491 (1956).
- (b) Hypothalamus et libération d'hormone lutéotrophique. Expériences de greffe hypophysaire chez la rat hypophysectomisée. Action lutéotrophique de l'ocytocine. *Ann. Endocr. (Paris)* **17**, 586—595 (1956).
- DICZFALUSY, E., TILLINGER, K. G., WESTMAN, A.: Studies on oestrogen metabolism in new born boys. I and II. *Acta endocr. (Kbh.)* **26**, 303—312 and 313—321 (1957).
- DIECKMANN, H.: Über die Histologie der Brustdrüse bei gestörtem und ungestörtem Menstruationsablauf. *Virchows Arch. path. Anat.* **256**, 321—356 (1925).
- DJOJOSOEBAGIO, S., TURNER, C. W.: (a) The effect of crystalline dihydrotachysterol on milk secretion in thyroparathyroidectomized lactating rats. *Proc. Soc. exp. Biol. (N. Y.)* **116**, 909—912 (1964).
- — (b) Effects of parathyroid extract calciferol, hytakerol and crystalline dihydrotachysterol on feed consumption in normal lactating rats. *Proc. Soc. exp. Biol. (N. Y.)* **116**, 646—648 (1964).
- — (c) Effects of parathyroid extract, dihydrotachysterol (hytakerol) and calciferol on milk secretion in rats. *Endocrinology* **74**, 554—558 (1964).
- DONOVAN, B. T., JACOBSON, D.: Testosterone and the growth of mammary glands and other tissues of hypophysectomized rats treated with thyroxine, insulin and cortisone. *Acta endocr. (Kbh.)* **33**, 214—229 (1960).
- DORFMAN, R. I., SHIPLEY, R. A.: In: *Androgens*. New York: J. Wiley & Son 1956.
- DUBOIS, J.: Méthode d'évolution quantitative du développement de la glande mammaire chez la souris traitée par des corps oestrogènes. *C. R. Soc. Biol. (Paris)* **138**, 149—151 (1944).
- DUMONT, J. N.: Prolactin — induced cytologic changes in the mucosa of the pigeon crop during crop-“milk” formation. *Z. Zellforsch.* **68**, 755—782 (1965).
- DURAN-REYNALS, F., BUNTING, H., WAGENEN, G. VAN: Studies on the sex skin of *Macaca mulatta*. *Ann. N. Y. Acad. Sci.* **52**, 1006—1014 (1950).
- EGGELING, H. VON: Die Milchdrüse. In: *Handbuch der mikroskopischen Anatomie des Menschen von v. MOELLENDORF, W.* Bd. 1, Berlin: Springer 1927.
- EISEN, M. J.: The occurrence of benign and malignant mammary lesions in rats treated with crystalline estrogene. *Cancer Res.* **2**, 632—644 (1942).
- EISENFELD, A. J., AXELROD, J.: Selectivity of estrogen distribution in tissues. *J. Pharmacol. exp. Ther.* **150**, 469—475 (1965).
- ELGER, W., BERSWORDT-WALLRABE, R. VON, NEUMANN, F.: Der Einfluß von Antiandrogenen auf androgenabhängige Vorgänge im Organismus. *Naturwissenschaften* **54**, 549—552 (1967).
- NEUMANN, F.: The role of androgens in differentiation of the mammary gland in male mouse fetuses. *Proc. Soc. exp. Biol. (N.Y.)* **123**, 637—640 (1966).
- ELLIS, R.: Fine structure of the myoepithelium of the eccrine sweat glands of man. *J. Cell Biol.* **27**, 551—563 (1965).
- EMGE, L. A.: Estrogenic hormones and carcinogenesis. *Surg. Gynec. Obstet.* **68**, 472—479 (1939).
- ESKIN, B. A., BARTUSKA, D. G., DUNN, M. R., JACOB, G., DRATMAN, M. D.: Mammary gland dysplasia in iodine deficiency studies in rats. *J. Amer. med. Ass.* **200**, 691—695 (1967).
- FAUVET, E.: Vergleichende Untersuchungen über die Entwicklung und Funktion der Milchdrüsen. V. Experimentelle Untersuchungen über den Einfluß der Ovarialhormone auf die Milchdrüsen der Ratten. *Arch. Gynäk.* **170**, 244—262 (1940).
- FERGUSON, D. J., VISSCHER, M. B.: The effects of androgen and estrogen in castrated and hypophysectomized C_3H mice. *Endocrinology* **52**, 463—473 (1953).
- Endocrine control of mammary glands in C_3H mice. *Surgery* **39**, 30—36 (1956).

- FERRERI, F. L., GRIFFITH, D. R.: Effect of hydrocortisone acetate on mammary gland nucleic content of pregnant rats. *Proc. exp. Soc. Biol. (N.Y.)* **130**, 1216—1218 (1969).
- FISCHER, R., SCHAEFER, H. E.: Geschlechtsdifferentes Vorkommen und östrogenabhängige Induktion der alkalischen Phosphatase in subkutanen Fibroblasten der Maus. *Naturwissenschaften* **54**, 342—343 (1967).
- FISKE, S. W. C., COURTECUISSE, V., HAGUENAU, F.: High resolution autoradiographic study of normal lactating mammary gland and mammary tumors of the mouse: Preliminary report. *J. nat. Cancer Inst.* **39**, 209—229 (1967).
- FLUX, D. S.: (a) Effect of 17-Vinyltestosterone on the mammae, uteri, thymus and adrenal glands of spayed female mice. *Proc. Soc. exp. Biol. (N. Y.)* **85**, 16—18 (1954).
- (b) The effect of adrenal steroids on the growth of the mammary glands, uteri, thymus and adrenal glands of intact, ovariectomized and oestrone-treated ovariectomized mice. *J. Endocr.* **11**, 238—254 (1954).
- Mammary gland growth in male mice of the CHI strain after hypophysectomy and castration. *J. Endocr.* **17**, 300—306 (1958).
- MUNFORD, R. E.: The effect of adrenocorticotropin on the mammary glands of intact nature female mice of the Chi strain. *J. Endocr.* **14**, 343—347 (1957).
- FOLLEY, S. J.: Lactation. *Biol. Rev.* **15**, 421—458 (1940).
- The physiology and biochemistry of lactation. Edinburgh and London: Oliver & Boyd 1956.
- (a) Endocrine control of the mammary gland. Mammary development. *Brit. med. Bull.* **5**, 130—134 (1947).
- (b) Lactation. *Brit. med. Bull.* **5**, 135—141 (1947).
- Some effects of steroids on the mammary gland. In: Ciba foundation Colloquia on Endocrinology, ed. by G. E. W. WOLSTENHOLME, vol. I, p. 69—86. London: J. & A. Churchill 1952.
- Hormones in mammary and function. *Brit. med. Bull.* **11**, 145—150 (1955).
- GREENBAUM, A. L.: Changes in the arginase and alkaline phosphatase contents of the mammary gland and liver of the rat during pregnancy, lactation and mammary involution. *Biochem. J.* **41**, 261—269 (1947).
- GUTKELCH, A. N., ZUCKERMAN, S.: The mammary gland of the rhesus monkey and normal and experimental conditions. *Proc. roy. Soc., London, Biol. Sci.* **126**, 469—491 (1939).
- MCNAUGHT, M. L.: Biosynthesis of milkfat. In: Milk, the mammary gland and its secretion, ed. by S. K. KON and A. T. COWIE, vol. 1, p. 441—479. New York and London: Academic Press 1961.
- YOUNG, F. G.: Prolactin as a specific lactogenic hormone. *Lancet* **1941**, 380—381.
- FOOTE, F. W., STEWART, F. W.: Lobular carcinoma in situ. A rare form of mammary cancer. *Amer. J. Path.* **17**, 491—496 (1941).
- — Comparative studies of cancerous versus noncancerous breasts. *Ann. Surg.* **121**, 197—222 (1945).
- FORBES, A. P., HENNEMAN, P. H., GRISWOLD, G. C., ALBRIGHT, F.: A syndrome, distinct from acromegaly, characterized by spontaneous lactation, amenorrhea, and low folliclestimulating hormone excretion. *J. clin. Endocr.* **11**, 749 (1951).
- — — Syndrome characterized by galactorrhoea, amenorrhoea and low urinary FSH: Comparison with acromegaly and normal lactation. *J. clin. Endocr.* **14**, 265—271 (1954).
- FORBES, TH. R.: Factor of age in the rate of absorption of, and in mammary stimulation by, testosterone monopropionate pellets in rats. *Endocrinology* **30**, 765—766 (1942).
- FORSSMANN, W. G.: Elektronenmikroskopische Morphologie der Sekretion des Taubenkopfes unter dem Einfluß von Prolaktin. *Frankfurt. Z. Path.* **74**, 512—533 (1965).

- FORSYTH, J. A., FOLLEY, S. J., CHADWICK, A.: Lactogenic and pigeon crop-stimulating activities of human pituitary growth hormone preparations. *J. Endocr.* **31**, 115—126 (1965).
- FRANTZ, V. K., PICKREN, J. W., MELCHER, G. W., AUCHINCLOSS, H.: Incidence of chronic cystic disease in so called "normal breasts". *Cancer (Philad.)* **4**, 762—783 (1951).
- FRAZIER, C. N., MU, J. W.: Development of female characteristics in adult male rabbits following prolonged administration of estrogenic substance. *Proc. Soc. exp. Biol. (N. Y.)* **32**, 997—1001 (1935).
- GARDNER, W. U.: Growth of the mammary glands in hypophysectomized mice. *Proc. Soc. exp. Biol. (N. Y.)* **45**, 835—837 (1940).
- Inhibition of mammary growth by large amounts of estrogen. *Endocrinology* **28**, 53—61 (1941).
- SMITH, G. M., STRONG, L. C.: Stimulation of abnormal mammary growth by large amounts of estrogenic hormone. *Proc. Soc. exp. Biol. (N. Y.)* **33**, 148—150 (1935).
- STRONG, L. C.: The normal development of the mammary glands of virgin female mice of ten strains varying in susceptibility to spontaneous neoplasma. *Amer. J. Cancer* **25**, 282—290 (1935).
- TURNER, C. W.: The function, assay, and preparation of galactin, a lactation stimulating hormone of the anterior pituitary. *Missouri Agr. Exp. Sta. Res. Bull.* **190** (1933).
- WHITE, A.: Mammary growth in hypophysectomized male mice receiving estrogen and prolactin. *Proc. Soc. exp. Biol. (N. Y.)* **48**, 590—592 (1941).
- GARRETT, F. A., TALMAGE, R. V.: The influence of relaxin on mammary gland development in guinea-pigs and rabbits. *J. Endocr.* **8**, 336—340 (1952).
- GESCHICKTER, C. F.: The endocrine aspects of chronic cystic mastitis. *Sth. Surg.* **10**, 457—486 (1941).
- Diseases of the breast, 2nd ed. Philadelphia-London-Montreal: Lippincott 1948.
- BYRNES, E. W.: Factors influencing the development and time of appearance of mammary cancer in the rat in response to estrogen. *Arch. Path.* **33**, 335—342 (1942).
- HARTMAN, C. G.: Mammary response to prolonged estrogenic stimulation in the monkey. *Cancer (Philad.)* **12**, 767—781 (1959).
- SPEERT, H.: *Zit. nach SPEERT*, 1948.
- GIRARDIE, J., WOLFF, E.: Localisation optique et ultrastructurale de l'activité phosphatase alcaline dans l'épithélium mammaire. *C. R. Acad. Sci. (Paris)* **264**, 2064—2067 (1967).
- GLOCK, G. E., MCLEAN, P.: Further studies on the properties and assays of glucose-6-phosphate-dehydrogenase and 6-phospho-gluconate-dehydrogenase of rat liver. *Biochem. J.* **55**, 400—408 (1954).
- — Levels of enzymes of the direct oxydative pathway of carbohydrate metabolism in mammalian tissues and tumors. *Biochem. J.* **56**, 171—175 (1954).
- GÖGL, H., LANG, F. J.: Brustdrüse. In: *Lehrbuch der spez. pathologischen Anatomie von E. KAUFMANN*, hrsg. von M. STAEMMLER, 11./12. Aufl., II. Bd., 1. Teil. Berlin: W. D. Gruyter & Co. 1957.
- GÖSSNER, W.: Histochemischer Nachweis hydrolytischer Enzyme mit Hilfe der Azofarbstoffmethode. *Histochemie* **1**, 48—96 (1959).
- GOLDENBERG, V. E., WIEGENSTEIN, L., MOTTET, N. K.: Florid breast fibroadenomas in patients taking hormonal oral contraceptives. *Amer. J. clin. Path.* **49**, 58—59 (1968).
- GOMEZ, E. T., TURNER, C. W.: Hypophysectomy and replacement therapy in relation to the growth and secretory activity of the mammary gland. *Res. Bull. Mo. agric. Exp. Sta. Nr.* 259 (1937).

- GORSKI, J., NOTEBOOM, W. D., NICOLETTE, J. A.: Estrogen control of the synthesis of RNA and protein in the uterus. *J. cell. comp. Physiol.* **66**, 91—110 (1965).
- GRAUMANN, W.: (a) Entwicklung des Milchstreifens. *Z. Anat. Entwickl.-Gesch.* **114**, 500—510 (1950).
- (b) Mikroskopische Anatomie der männlichen Brustdrüse. 1. Kindheit und Pubertät. *Z. mikr.-anat. Forsch.* **59**, 358—380 (1952).
- (c) Mikroskopische Anatomie der männlichen Brustdrüse. 2. Mannesalter und Senium. *Z. mikr.-anat. Forsch.* **59**, 523—557 (1953).
- GREEN, J. D., HARRIS, G. W.: The neurovascular link between the neurohypophysis and adenohypophysis. *J. Endocr.* **5**, 136—145 (1946/48).
- GREENBAUM, A. L., SLATER, T. F.: Studies on the particulate components of rat mammary gland. II. Changes in the levels of the nucleic acids of the mammary glands of rats during pregnancy, lactation and mammary involution. *Biochem. J.* **66**, 155—161 (1957).
- GREGG, W. I.: Galactorrhoea after contraceptive hormones. *New Engl. J. Med.* **274**, 1432—1434 (1966).
- GRIFFITH, D. R., TURNER, C. W.: Desoxyribonucleic acid (DNA) content of mammary gland during pregnancy and lactation. *Proc. Soc. exp. Biol. (N.Y.)* **95**, 347—348 (1957).
- — Normal growth of rat mammary glands during pregnancy and lactation. *Proc. Soc. exp. Biol. (N.Y.)* **102**, 619—621 (1959).
- — (a) Normal growth of rat mammary glands during pregnancy and early lactation. *Proc. Soc. exp. Biol. (N.Y.)* **106**, 448—451 (1961).
- — (b) Thyroxine and mammary gland growth in rat. *Proc. Soc. exp. Biol. (N.Y.)* **106**, 873—874 (1961).
- — (c) Normal and experimental involution of rat mammary gland. *Proc. Soc. exp. Biol. (N.Y.)* **107**, 668—670 (1961).
- GROSVENOR, C. E., TURNER, C. W.: (a) Evidence for adrenergic and cholinergic components in milk let down reflex in lactating rats. *Proc. Soc. exp. Biol. (N.Y.)* **95**, 719—722 (1957).
- — (b) Release and restoration of pituitary lactogen in response to nursing stimuli in lactating rats. *Proc. Soc. exp. Biol. (N.Y.)* **96**, 723—725 (1957).
- GRUBER, G. B.: Über die Milchdrüenschwellung bei Neugeborenen. *Z. Kinderheilk.* **30**, 336—362 (1921).
- GRUMBRECHT, P.: Pathologische Auswirkungen des Follikelhormones. *Arch. Gynäk.* **170**, 1—59 (1941).
- HAAGENSEN, C. D.: Diseases of the breast. Philadelphia: W. B. Saunders 1956.
- HABBE, K.: Beitrag zur Frage über Granulosazelltumoren. *Zbl. Gynäk.* **55**, 1088 (1931).
- HADFIELD, D.: The nature and origin of the mammotrophic agent present in human female urine. *Lancet* **1957 I**, 1058—1061.
- YOUNG, S.: The controlling influence of the pituitary on the growth of the normal breast. *Brit. J. Surg.* **46**, 265—273 (1958).
- HAENEL, H.: Ein Fall von dauernder Milchsekretion beim Manne. *Münch. med. Wschr.* **75**, 261—263 (1928).
- HAGUENAU, F.: (a) Le cancer mammaire de la souris et de la femme étude comparative au microscope électronique. *Path. et Biol.* **7**, 989—1015 (1959).
- (b) Les myofilaments de la cellule myoepitheliale. Etude au microscope électronique. *C. R. Acad. Sci. (Paris)* **249**, 182—184 (1959).
- ARNOULT, J.: (c) Le cancer du sein chez la femme. *Bull. Ass. franç. Cancer* **46**, 177—211 (1959).
- HAMADA, H., NEUMANN, F., JUNKMANN, K.: Intrauterine antimaskuline Beeinflussung von Rattenfeten durch ein stark gestagen wirksames Steroid. *Acta endocr. (Kbh.)* **44**, 380—388 (1963).

- HAMBERGER, L., AHRÉN, K.: Influence of the adrenal cortex on growth processes in the rat mammary gland. *J. Endocr.* **30**, 171—179 (1964).
- HAMPERL, H.: Über die Myothelien (myo-epitheliale Elemente) der Brustdrüse. *Virchows Arch. path. Anat.* **305**, 171—215 (1940).
- HANCOCK, J., BRUMBY, P. J., TURNER, C. W.: Hormonal induction of lactation in identicaltwin dairy cattle. *N. Z. J. Sci. Tech. A*, **36**, 111—116 (1954).
- HANSEN, R. G., CARLSON, D. M.: General biochemistry of mammary tissue. In: *Milk, the mammary gland and its secretion*, ed. by S. K. KON and A. T. COWIE, vol. 1, p. 371—388. New York and London: Academic Press 1961.
- HARDY, M. H.: The Development in vitro of the Mammary Glands of the mouse. *J. Anat. (Lond.)* **84**, 388—393 (1950).
- HARTMANN, M.: Einführung in die allgemeine Biologie. Sammlung Göschen, Sammlung Bd. 96, 1956.
- HAYASHIDA, T.: Further observations on the question of specificity of antihuman growth hormone rabbit serum. *Endocrinology* **70**, 846—856 (1962).
- HELMINEN, H. J., ERICSSON, L. E., ORRENIUS, S.: Studies on the mammary gland involution. IV. Histochemical and biochemical observations on alterations in lysosomes and lysosomal enzymes. *J. Ultrastruct. Res.* **25**, 240—252 (1968).
- HEROLD, L., EFFKEMANN, G.: Beziehungen des Follikelhormons zu patho-physiologischen Wachstumsvorgängen der Brustdrüse. *Arch. Gynäk.* **163**, 85—93, 94—101, 309—315 (1936).
- HEUVERSWEYN, J. VAN, FOLLEY, S. J., GARDNER, W. U.: Mammary growth in male mice receiving androgens, estrogens and desoxycorticosterone acetate. *Proc. Soc. exp. Biol. (N. Y.)* **41**, 389—392 (1939).
- HIBBS, R. G.: The fine structure of the human eccrine sweat glands. *Amer. J. Anat.* **103**, 201—218 (1958).
- HIGASHI, K.: Studies on the prolactin-like substance in human placenta. *Endocrin. Jap.* **9**, 1—11 (1962).
- HIGUCHI, K.: Die Gewebsmastzellen in der Mamma. *Fol. haemat. (Lpz.)* **40**, 401—414 (1930).
- HÖHN, E. O.: The effect of oestrone on the mammary gland of adrenalectomized guinea-pigs. *J. Endocr.* **16**, 227—230 (1957).
- HOFFMANN, F.: Über die Wirkung des Follikelhormons auf den histologischen Aufbau der menschlichen Brustdrüse. *Zbl. Gynäk.* **63**, 422—426 (1939).
- HOLMES, R.: Alkaline phosphatase in the rabbit mammary gland. *Nature (Lond.)* **178**, 311 (1956).
- HOLZNER, J. H., KAUFMANN, F.: Histochemische Untersuchungen über das Verhalten der Phosphatasen bei der zyklischen Mastopathie, beim Fibroadenom und Karzinom der menschlichen Brustdrüse. *Krebsarzt* **20**, 185—192 (1965).
- HOSHINO, K.: Development and growth of mammary glands of CBA mice prenatally exposed to progesterone. *Anat. Rec.* **154**, 360 (1966).
- HUGHES, E. S. R.: The Development of the Mammary Gland. *Ann. roy. Coll. Surg. Eng.* **6**, 99—119 (1950).
- HUMBOLDT, A. v.: *Aus: Reise in die Aequinoktialgegenden*. Ges. Werke, Stuttgart, Bd. 5, S. 230 (1889).
- HUMPHREY, L. J., SWEDLOW, M.: The relationship of breast disease to thyroid disease. *Cancer (Philad.)* **17**, 1170—1173 (1964).
- HUNTER, J.: *Observation on certain parts of the animal oconomy*, p. 191—198: On a secretion in the crop of breeding pigeons, for the nourishment of their young. London 1786.
- IHNEN, M., PEREZ-TAMAYO, R.: Breast stroma; morphological and histochemical study. *Arch. Path.* **56**, 46—67 (1953).
- INGLEBY, H.: Normal and pathologic proliferation in the breast with special reference to cystic disease. *Arch. Path.* **33**, 573—589 (1942).

- JACOBSON, D.: Action of estradiol monobenzoate on the mammary glands of hypophysectomized rabbits. *Acta physiol. scand.* **32**, 304—313 (1954).
- Thyroxin and the reaction of the mammary glands to ovarian steroids in hypophysectomized rats. *J. Physiol. (Proc. Physiol. Soc.)* **148**, 10—11 (1959).
- Effects of thyroxine on growth of mammary glands, whole body, heart and liver in hypophysectomized rats treated with Insulin, Cortisone and ovarian steroids. *Acta endocr. (Kbh.)* **35**, 107—134 (1960).
- Hormonal Regulation of Mammary Gland growth. In: *Milk: The mammary gland and its secretion* by KON, S. K. and A. T. COWIE, vol. 1, p. 127—160. New York and London: Academic Press 1961.
- Modification by oestrogens of the reaction of the rat's mammary gland to androgens. *Acta endocr. (Kbh.)* **41**, 88—100 (1962).
- NORGREN, A.: Estrogens and corticoids in relation to mammary gland growth in male rats. *Proc. Soc. exp. Biol. (N. Y.)* **118**, 1106—1109 (1965).
- JAKOBOVITS, A.: Extrapuerperale Milchabsonderung nach Kastration. *Zbl. Gynäk.* **82**, 438—441 (1960).
- JEFFERS, K. R.: Cytology of the mammary gland of the albino rat. I. Pregnancy, lactation and involution. *Amer. J. Anat.* **56**, 257—277 (p 35).
- JENSEN, E. V., JACOBSON, H. J.: Basii guides to the mechanism of oestrogen action. *Recent Progr. Hormone Res.* **18**, 387—414 (1962).
- JERVELL, K. J., DINIZ, C. R., MUELLER, G. C.: Early effects of estradiol on nuclei acid metabolism in the rat uterus. *J. biol. Chem.* **231**, 945—948 (1958).
- JOHNSON, R. M.: The effects of cortisone on lactation in rats. *J. Anim. Sci.* **15**, 1288 (1956).
- Effects of cortisone on lactation and involution of mammary glands in rats. *J. Dairy Sci.* **40**, 625 (1957).
- MEITES, J.: Effects of cortisone, hydrocortisone and ACTH on mammary growth and pituitary prolactin content of rats. *Proc. Soc. exp. Biol. (N. Y.)* **89**, 455—458 (1955).
- JONES, D. B.: Florid papillomatosis of the nipple ducts. *Cancer (Philad.)* **8**, 315—319 (1955).
- JOSIMOVICH, J. B., McLAREN, J. A.: Presence in the human placenta and their serum of a highly lactogenic substance immunologically related to pituitary growth hormone. *Endocrinology* **71**, 209—220 (1952).
- JUNKMANN, K.: Die physiologische Chemie der inneren Sekretion. In: *FLASCHEN-TRÄGER-LEHNARTZ, Handbuch der physiologischen Chemie, Bd. II. Der Stoffwechsel, 2. Teil/Bandteil 6, S. 485—488.* Berlin-Göttingen-Heidelberg: Springer 1957.
- NEUMANN, F.: Zum Wirkungsmechanismus von an Feten antimaskulin wirkenden Gestagenen. *Acta endocr. (Kbh.) Suppl.* **90**, 139—154 (1964).
- KARLSON, P.: Biochemische Wirkungsweise der Hormone. *Dtsch. med. Wschr.* **86**, 668—674 (1961).
- Morphogenese und Metamorphose der Insekten. 13. Colloquium Ges. physiol. Chemie, S. 101—126 (1962).
- Chemie und Biochemie der Insektenhormone. *Angew. Chemie* **75**, 257—265 (1963).
- KARSNER, H. T.: Gynecomastia. *Amer. J. Path.* **22**, 235—315 (1946).
- KING, R. J. B., GORDON, J., INMAN, D. R.: The intracellular localization of oestrogen in rat tissues. *J. Endocr.* **32**, 9—15 (1965).
- GORDON, J., COWAN, D. M., INMAN, D. R.: The intranuclear localization of 6,7-³H oestradiol-17- β in dimethyl-benzanthracen-induced. Rat mammary adenocarcinoma and other tissue. *J. Endocr.* **36**, 139—150 (1966).
- KIRKHAM, W. R., TURNER, C. W.: Nucleic acids of the mammary glands of rats. *Proc. Soc. exp. Biol. (N.Y.)* **83**, 123—126 (1953).
- — Introduction of mammary growth in rats by estrogen and progesterone. *Proc. Soc. exp. Biol. (N. Y.)* **87**, 139—141 (1954).

- KOCHAKIAN, C. D.: Regulation of ribonucleic acid biosynthesis in the mouse kidney by androgens. Proc. 2nd Internat. Congr. on Hormonal Steroids, 1967, p. 794—802.
- KOELLIKER, A.: Mikroskopische Anatomie oder Gewebelehre des Menschen, 2 Bd. Spezielle Gewebelehre. Leipzig. Engelmann 1852.
- KON, S. K., COWIE, A. T.: Milk. The mammary gland and its secretion, vol. I. u. II. New York and London: Academic Press 1961.
- KONJETZNY, G. E.: Pathologie, Klinik und Behandlung der Mastopathie. Stuttgart 1942.
- Mastopathie und Milchdrüsenkrebs. Stuttgart: Enke Verlag 1954.
- KRACHT, J., HACHMEISTER, M., BREUSTEDT, H.-J., ZIMMERMANN, H.-D.: Immunhistologische Hormonlokalisation im Hypophysenvorderlappen des Menschen. *Materia Medica Nordmark* XIX/4, 224—238 (1967).
- KRAUS, E. J.: Zur Pathogenese der Galaktorrhoe. *Arch. Gynäk.* **159**, 380—394 (1935).
- KUECKENS, H.: Zur Frage der zyklischen Veränderungen der Mamma und des menschlichen Scheidenepithels. *Z. Geburtsh.* **96**, 55—76 (1929).
- KUNERT, J.: Die Wirkung hoher Dosen örtlich verabreichten Follikelhormons auf die männliche Brustdrüse und das endokrine System. Experimentelle Studie zum Gynäkomastieproblem. Frankfurt. *Z. Path.* **62**, 373—383 (1951).
- KURU, H.: Beiträge zur Geschwulstlehre. *Dtsch. Z. Chir.* **98**, 414—463 (1909).
- KUZMA, J. F.: Myoepithelial proliferations in the human breast. *Amer. J. Path.* **19**, 473—489 (1943).
- LABHART, A.: Klinik der inneren Sekretion. Berlin-Göttingen-Heidelberg: Springer 1957.
- LANGER, E., HUHN, S.: Der submikroskopische Bau der Myoepithelzelle. *Z. Zellforsch.* **47**, 507—516 (1958).
- LANI, K.: Enzymhistochemische und morphologische Untersuchungen über die Prolaktinwirkung auf die Mamma. Inaug.-Diss. Mainz 1967.
- BÄSSLER, R.: Tagg der nord- und westdeutschen Pathologen in Lüneburg 1967. *Zbl. allg. Path. path. Anat.* **111**, 473 (1968).
- LAQUEUR, E., DE JONGH, S. E.: Zur Wirkung des weiblichen Sexualhormons Menformon, im besonderen auf die Mamma. *M Schr. Geburtsh.* **80**, 245 (1928).
- LAQUEUR, G. L.: Effects of testosterone propionate on the mammary glands of female albino rats. *Endocrinology* **32**, 81—86 (1943).
- FLUHMANN, C. F.: Effects of testosterone propionate in immature and adult female rats. *Endocrinology* **30**, 93—101 (1942).
- LAURITZEN, C.: Oestrogene und Gestagene beim Menschen. *Naturw. Rdsch.* **18**, 7—16 (1965).
- LEESON, R.: (a) The histochemical identification of myoepithelium with particular reference to the Harderian and exorbital lacrimal glands. *Acta anat. (Basel)* **40**, 87—94 (1960).
- (b) The electron microscopy of the myoepithelium in the rat exorbital lacrimal gland. *Anat. Rec.* **137**, 45—55 (1960).
- LEONARD, S. L.: Stimulation of mammary glands in hypophysectomized rats by estrogen and testosterone. *Endocrinology* **32**, 229—237 (1943).
- REECE, R. P.: The relation of the thyroid to mammary gland growth in the rat. *Endocrinology* **28**, 65—69 (1941).
- — Failure of steroid hormones to induce mammary growth in hypophysectomized rats. *Endocrinology* **30**, 32—36 (1942).
- LETTERER, E.: Die Morphologie der hormonalbedingten Veränderungen des Endometriums und der weiblichen Brustdrüse. *Ärztl. Wschr.* **1948**, 230—236.
- LEUSCHNER, U.: Über die Lokalisation von Mucopolysacchariden und Mastzellen in scirrhösen Karzinomen der Mamma. *Acta histochem. (Jena)* **34**, 126—137 (1969).

- LEVINE, H. J., BERGENSTAL, D. M., THOMAS, L. B.: Persistent lactation: Endocrine and histologic studies in 5 cases. *Amer. J. med. Sci.* **243**, 118—128 (1962).
- LEWIS, A. A., GOMEZ, E. T., TURNER, C. W.: Mammary gland development with mammogen in the castrate and the hypophysectomized rat. *Endocrinology* **30**, 37—47 (1942).
- TURNER, C. W.: Effect of stilbestrol on the mammary gland of the mouse, rat, rabbit and goat. *J. Dairy Sci.* **24**, 845—860 (1941).
- — (a) Growth of the male guinea pig mammary gland with diethylstilbestrol. *Endocrinology* **30**, 585—590 (1942).
- — (b) Mammogen and unilateral mammary growth in the rabbit. *Endocrinology* **30**, 985—989 (1942).
- LIESER, H.: Beiträge zur Histologie und Feinstruktur der Mamma unter dem Einfluß von Geschlechtshormonen. Diss. Mainz 1964.
- LINZELL, J. L.: The silver staining of myoepithelial cells, particularly in the mammary gland, and their relation of the ejection of milk. *J. Anat. (Lond.)* **86**, 49—57 (1952).
- Some observations on the contractile tissue of the mammary glands. *J. Physiol. (Lond.)* **130**, 257—267 (1955).
- LITTEN, L.: Die histologischen Grundlagen der Sekretion nicht-gravider Mammae. *Virchows Arch. path. Anat.* **259**, 126—146 (1926).
- LITWER, G.: Die histologischen Veränderungen der Kropfwanderung bei Tauben zur Zeit der Bebrütung und Ausfütterung ihrer Jungen. *Z. Zellforsch.* **3**, 695—722 (1926).
- LUCHSINGER, Y., CENTENO, J.: Über die zyklischen Veränderungen der weiblichen Brustdrüse. *Beitr. path. Anat.* **78**, 594—617 (1927).
- LUSTIG, H.: Zur Entwicklungsgeschichte der menschlichen Brustdrüse. *Arch. mikr. Anat.* **87**, 38—59 (1915).
- LYONS, W. R.: The hormonal basis for "witches milk". *Proc. Soc. exp. Biol. (N. Y.)* **37**, 207—209 (1938).
- The direct mammatrophic action of lactogenic hormone. *Proc. Soc. exper. Biol. (N. Y.)* **51**, 308—311 (1942).
- Lobulo-alveolar mammary growth in the rat. *Colloq. int. Cent. nat. Rech. sci.* No. **32**, 29—38 (1951).
- CATCHPOLE, H. R.: (a) "Assay with the guinea pig of the lactogenic hypophyseal hormone". *Proc. Soc. exp. Biol. (N. Y.)* **31**, 299—301 (1933).
- — (b) "Availability of the rabbit for assay of the hypophyseal lactogenic hormone. *Proc. Soc. exp. Biol. (N. Y.)* **31**, 305—309 (1933).
- JOHNSON, R. E., COLE, R. D., LI, C. H.: Mammary growth and lactation in male rats. In: *The hypophyseal growth hormone, nature and actions* (eds. R. W. SMITH, O. A. GAEBLER and C. N. H. LONG), p. 461—472. New York: The Blakiston Division 1955.
- LI, C. H., JOHNSON, R. E.: Localaction of pituitary and ovarian hormones on the mammary glands of hypophysectomized-oophorectomized rats. *Anat. Rec.* **127**, 432—433 (1957).
- — — The hormonal control of mammary growth and lactation. *Recent Progr. Hormone Res.* **14**, 219—254 (1958).
- MCGINTY, D. A.: Effects of estrone and progesterone on male rabbit mammary gland. I. Varying doses of progesterone. *Proc. Soc. exper. Biol. (N. Y.)* **48**, 83—86 (1941).
- MAEDER, L. M. A.: Changes in the mammary gland of the albino rat (*Mus norvegicus albus*) during lactation and involution. *Amer. J. Anat.* **31**, 1—26 (1922/23).
- MAHESH, V. B., DALLA PRIA, S., GREENBLATT, R. B.: Abnormal lactation with Cushing's syndrome—a case report. *J. clin. Endocr.* **29**, 978—981 (1969).
- MASSHOFF, W.: Die physiologische Regeneration. In: *Handbuch der allgemeinen Pathologie*, Bd. VI/1, S. 489, von F. BÜCHNER, E. LETTERER und F. ROULET. Berlin-Göttingen-Heidelberg: Springer 1955.

- MAYER, G., KLEIN, M.: Histology and cytology of the mammary gland. In: Milk: The mammary gland and its secretion, ed. by S. K. KON and A. T. COWIE, vol. I, p. 47—126. New York and London: Academic Press 1961.
- McCULLAGH, E., ALIVISATOS, J. G., SCHAFFENBURG, C. A.: Pituitary tumor with gynecomastia and lactation. *J. clin. Endocr.* **16**, 397—405 (1956).
- McDONALD, G. J., REECE, R. P.: Quantitative response of rat mammary glands to mammogens. I. Estrogen alone with progesterone. *Proc. Soc. exp. Biol. (N. Y.)* **110**, 647—649 (1962).
- McEuen, C. S.: Some effects of prolonged administration of oestrin in rats. *Lancet* **1936 I**, 775—776.
- Role of pituitary in effect of testosterone on the mammary gland. *Proc. Soc. exp. Biol. (N. Y.)* **36**, 213—215 (1937).
- SELYE, H., COLLIP, J. B.: Effect of the testis on the mammary gland. *Proc. Soc. exp. Biol. (N. Y.)* **35**, 56—58 (1936).
- MEIER-RUGE, W.: Die diagnostische Bedeutung des Sexchromatingehaltes in Relation von Enzymhistochemie, DNS-Gehalt und Mitoseindex beim Mammacarcinom. *Verh. dtsch. Ges. Path.* **50**, 330—335 (1966).
- MEITES, J.: (a) Mammary growth and lactation. In: Reproduction in domestic animals, ed. by H. H. COLE and P. T. CUPPS, vol. I, p. 539—593. New York and London: Academic Press 1959.
- (b) Induction and maintenance of mammary growth and lactation in rats with acetylcholin or epinephrine. *Proc. Soc. exp. Biol. (N. Y.)* **100**, 750—754 (1959).
- Farm animals: hormonal induction of lactation and galactopoesis. In: Milk: The mammary gland and its Secretion, ed. by S. K. KON and A. T. COWIE. New York: Academic Press 1961.
- Maintenance of the mammary lobuloalveolar system in rats after adrenoorchidectomy by prolactin and growth hormone. *Endocrinology* **76**, 1220—1223 (1965).
- Effects of altering the balance between prolactin and ovarian hormones on initiation of lactation in rabbits. *Endocrinology* **55**, 530—534 (1954).
- SGOURIS, J. T.: Can the ovarian hormones inhibit the mammary response to the prolactin? *Endocrinology* **53**, 17—23 (1953).
- TURNER, C. W.: The induction of lactation during pregnancy in rabbits on the specificity of the lactogenic hormone. *Amer. J. Physiol.* **150**, 394—399 (1947).
- MERZ, W.: Brustdrüsenanschwellung bei Neugeborenen. *Schweiz. med. Wschr.* **11**, 213—217 (1946).
- MEYER, H.: Experimentelle Pathomorphogenese der Mamma unter dem Einfluß männlicher Geschlechtshormone. Inaug.-Diss. Mainz, 1967.
- MIXNER, J. P.: Influence of environmental temperature on growth of mammary lobule-alveolar system. *Proc. Soc. exp. Biol. (N. Y.)* **48**, 443—445 (1941).
- (a) Role of estrogen in the stimulation of mammary lobule-alveolar growth by progesterone and by the mammogenic lobule-alveolar growth factor of the anterior pituitary. *Endocrinology* **30**, 591—597 (1942).
- (b) Progesterone like-activity of some steroid compounds and of diethylstilbestrol in stimulating mammary lobule-alveolar growth. *Endocrinology* **30**, 706—710 (1942).
- (c) Influence of thyroxine upon mammary lobule-alveolar growth. *Endocrinology* **31**, 345—348 (1942).
- The mammogenic hormones of the anterior pituitary. II. The lobulo-alveolar growth factor. *Res. Bull. Mo. agric. Exp. Sta.* **378** (1943).
- Strain differences in response of mice to mammary gland stimulating hormones. *Proc. Soc. exp. Biol. (N. Y.)* **95**, 87—89 (1957).
- TURNER, C. W.: Growth of the lobule-alveolar system of the mammary gland with pregnenolone. *Proc. Soc. exp. Biol. (N. Y.)* **47**, 453—456 (1941).

- MÖBIUS, G., NIZZE, H.: Mastopathia fibrosa cystica und Epithelproliferationen in der weiblichen Brustdrüse des Sektionsgutes. Frankfurt. Z. Path. **75**, 297—305 (1966).
- MOON, R. C.: Mammary gland cell content during various phases of lactating. Amer. J. Physiol. **203**, 939—941 (1962).
- Influence of graded thyroxin levels on mammary gland growth. Amer. J. Physiol. **203**, 942—946 (1962).
- GRIFFITH, D. R., TURNER, C. W.: Normal and experimental growth of rat mammary gland. Proc. Soc. exp. Biol. (N. Y.) **101**, 788—790 (1959).
- TURNER, C. W.: Thyroid hormone and mammary growth in the rat. Proc. Soc. exp. Biol. (N. Y.) **103**, 149—151 (1960).
- MOSIMANN, W.: Vergrößerung der Kernvolumina in der Parathyreoidea und vermehrte Kalziumausscheidung in der Milch bei Ziegen nach künstlicher Auslösung der Laktation durch Oestrogen. Schweiz. Arch. Tierheilk. **97**, 178—187 (1955).
- Das Volumen der Zellkerne im Epithel der Milchdrüse in Abhängigkeit vom Funktionszustand und bei Stilboestrol-Zufuhr. Z. mikr.-anat. Forsch. **63**, 303—316 (1957).
- MÜHLBROCK, O.: The oestrone-sensitivity of the mammary gland in female mice of various strains. Acta brev. neerl. physiol. **16**, 22—27 (1948).
- MÜLLERHEIM, R.: Ovarialtumoren bei Greisinnen mit Hypertrophie der Mammae und des Uterus und mit uterinen Blutungen. Zbl. Gynäk. **52**, 689 (1928).
- MUNFORD, R. E.: The effect of cortisol acetate on oestrone-induced mammary growth in immature ovariectomized albino mice. J. Endocr. **16**, 72—79 (1957).
- A review of anatomical and biochemical changes in the mammary gland with particular reference to quantitative methods of assessing mammary development. Dairy Sci., Abstr. **26**, 293—304 (1964).
- MUNGER, B. L.: The ultrastructure and histophysiology of human eccrine sweat glands. J. biophys. biochem. Cytol. **11**, 385—402 (1961).
- MUNSON, P. L.: Studies on the role of the parathyroids in calcium and phosphorus metabolism. Ann. N. Y. Acad. Sci. **60**, 776—795 (1955).
- MURAD, T. M., HAAM, E. v.: Ultrastructure of myoepithelial cells in human mammary gland tumors. Cancer (Philad.) **21**, 1137—1149 (1968).
- MYLIUS, E. A.: The identification and the role of the myoepithelial cell in salivary gland tumors. Acta path. microbiol. scand., Suppl. **139**, 50 (1960).
- NANDI, S.: (a) Role of somatotropin in mammarygenesis and lactogenesis in C₃H/He CRGL mice. Science **128**, 772—774 (1958).
- (b) Endocrine control of mammary gland development and function in the C₃H/He CRGL mouse. J. nat. Cancer Inst. **21**, 1939—1963 (1958).
- (c) Hormonal control of mammarygenesis and lactogenesis in the C₃H-He crgl. mouse. Univ. Calif. Publ. Zool. **65**, 1—128 (1959).
- NEEDHAM, D. M., SHOENBERG, C. F.: Proteins of the contractile mechanisms of mammalian an smooth muscle and their possible location in the cell. Proc. roy. Soc., Ser. B (London) **160**, 517—522 (1964).
- NEIMEIER, R., HAUSER, G. A., KELLER, M., LABHARDT, F., WENNER, R., STAMPFLI, V.: Die pathologische Lactation. Schweiz. med. Wschr. **89**, 442—445 (1959).
- NELSON, W. O.: Endocrine control of the mammary gland. Physiol. Rev. **16**, 488—526 (1936).
- Studies on the physiology of lactation. VI. The endocrine influences concerned in the development and function of the mammary gland in the guinea pig. Amer. J. Anat. **60**, 341—365 (1937).
- (a) Growth of mammary gland following local application of estrogenic hormone. Amer. J. Physiol. **133**, 397—398 (1941).
- (b) Production of sex hormones in the adrenals. Anat. Rec., Suppl. **1**, **81**, 97 (1941).

- NELSON, W. O., HEYTLER, P. G., CIACCO, E. I.: Guinea pig mammary gland growth changes in weight, nitrogen and nucleic acids. *Proc. Soc. exp. Biol. (N. Y.)* **109**, 373—375 (1962).
- MERCKEL, C. G.: Effects of androgenic substances in the female rat. *Proc. Soc. exp. Biol. (N. Y.)* **36**, 823—825 (1937).
- NEUMANN, F., ELGER, W.: The effect of the anti-androgen 1,2 α -methylene-6-chloro- Δ 4,6 pregnandiene-17 α -ol-3,20-dione-17 α -acetate (cyproterone-acetate) on the development of the mammary glands of male foetal rats. *J. Endocr.* **36**, 347—352 (1966).
- — Steroid stimulation of mammary glands in prenatally feminized male rats. *Europ. J. Pharmacol.* **1**, 120—123 (1967).
- — BERSWORDT-WALLRABE, R. VON: The structure of the mammary glands and lactogenesis in feminized male rats. *J. Endocr. (Lond.)* **36**, 353—356 (1966).
- NEUMANN, H. O., OING, M.: Polymastie und Polythelie. Eine klinische Studie mit einem entwicklungsgeschichtlich-historischen Beitrag. *Arch. Gynäk.* **13**, 494—542 (1929).
- NEWMAN, W.: In situ lobular carcinoma of the breast. Report of 26 woman with 32 cases. *Ann. Surg.* **157**, 591—599 (1963).
- Lobular carcinoma of the female breast. Report of 73 cases. *Ann. Surg.* **164**, 305—314 (1966).
- NICOLL, C. S.: Growth autoregulation and the mammary gland. *J. nat. Cancer Inst.* **34**, 131—140 (1965).
- MEITES, J.: Prolactin secretion in vitro: effects of thyreoid hormones and insulin. *Endocrinology* **72**, 544—551 (1963).
- NOBLE, R. L., MCEUEN, C. S., COLLIP, J. B.: Mammary tumors produced in rats by the action of estrone tablets. *Canad. med. Ass. J.* **42**, 412—417 (1940).
- NORDMANN, M.: Fibrosis mammae virilis. *Klin. Wschr.* **26**, 220—221 (1948).
- NORGREN, A.: Effects of different doses of oestrogen and progesterone on mammary glands of gonadectomized rabbits. *Acta Univ. Lund. Sectio II, No. 31* (1966).
- NYIRJESY, I.: Galactorrhoea without amenorrhoea. *J. Obstet, Gynec.* **32**, 52—57 (1968).
- OESTEREICH, R., SLAWYK: Riesenwuchs und Zirbeldrüsen-Geschwulst. *Virchows Arch. path. Anat.* **157**, 475—484 (1899).
- OLIVI, M., BARBIERI, G.: La mastopathia fibrocistica. *Lav. Ist. Anat. Univ. Perugia* **12**, 311—323 (1952).
- OVERZIER, C.: Gynäkomastie bei paradoxer Fettsucht — ein Beitrag zum Gynäkomastieproblem. *Ärztl. Wschr.* **4**, 4—10 (1949).
- OZZELLO, L., SPEER, F. D.: The mucopolysaccharides in the normal and diseased breast. Their distribution and significance. *Amer. J. Path.* **34**, 993—1009 (1958).
- PAEK, S.: Histochemisches Enzymmuster der Mamma unter dem experimentellen Einfluß von Geschlechtshormonen. *Inaug.-Diss. Mainz*, 1967.
- PERRINI, F.: Action of stilboestrol and progesterone on the mammary gland. *G. Ostet. Ginec.* **17**, 59—74 (1953).
- PHILIPP, E.: Schwangerschaftsveränderungen beim Neugeborenen. *Klin. Wschr.* **17**, 797—800 (1938).
- PRICE, D., WILLIAMS-ASHMAN, H. G.: The accessory reproductive glands of mammals. In: *Sex and internal cretions*, 3d, ed. by YOUNG, W. C., p. 366—448. Williams & Wilkins 1961.
- RAPOPORT, S. M.: *Medizinische Biochemie*, Berlin 1962.
- RATZENHOFER, M.: Zum Verhalten des Mesenchyms bei chronischer Mastopathie und Mammacarcinom. *Wien. med. Wschr.* **101**, 681—686 (1951).
- SCHAUNSTEIN, E.: (a) Weitere biophysikalische Untersuchungen des Gewebessaftes bei Mammacarcinom. *Z. Krebsforsch.* **58**, 707—710 (1952).

- RATZENHOFER, M., SCHAUENSTEIN, E.: (b) Über den Nachweis von Albuminen im Gewebssaft bei krebsig entarteter Mastopathie. *Z. Krebsforsch.* **58**, 198—200 (1952).
- RAY, E. W., AVERILL, S. C., LYONS, W. R., JOHNSON, R. E.: Rat placental hormone activities corresponding to those of pituitary mammatropin. *Endocrinology* **56**, 359—373 (1955).
- RAYNAUD, A.: (a) Effet des injections d' hormones sexuelles à la souris gravide, sur le développement des ébauches de la glande mammaire des embryous. I. Action des substances androgènes. *Ann. Endocr. (Paris)* **8**, 248—253 (1947).
- (b) Action de fortes doses des substances oestrogènes. *Ann. Endocr. (Paris)* **8**, 318—329 (1947).
- (c) Inhibition du développement des ébauches mammaires de l'embryon de souris sous l'effet d'une hormone oestrogène injectée directement à l'embryon. *C. R. Soc. Biol. (Paris)* **146**, 544—549 (1952).
- (d) Morphogenesis of the mammary gland. In: *Milk: The mammary gland and its secretion*, ed. by S. K. KON, and A. T. COWIE, vol. I, p. 1—46. New York and London: Academic Press 1961.
- (f) Le développement embryonnaire de la glande mammaire de la souris après destruction au moyen des rayons X des glandes génitales de l'embryon. *Bull. Soc. zool. France*, **74**, 156—159 (1949).
- (h) La production expérimental de malformations mammaires chez les foetus de souris par l'action des hormones sexuelles. *Ann. Inst. Pasteur* **90**, 39—219 (1956).
- FRILLEY, M.: (e) Etat de développement des ébauches mammaires et du cordon vaginal chez le foetus mâles et femelles de souris, dont les ébauches des glandes génitales ont été détruites par une irradiation au moyen des rayon X, à l'âge de treize jours. *C. R. Acad. Sci. (Paris)* **225**, 1380—1382 (1947).
- RAYNAUD, J.: (g) Les diverses malformations mammaires produites chez les foetus de souris, par l'action des hormonelles sexuelles. *C. R. Soc. Biol. (Paris)* **148**, 963—968 (1954).
- REECE, R. P., MIXNER, J. P.: Effect of testosterone on pituitary and mammary gland. *Proc. Soc. exp. Biol. (N. Y.)* **40**, 66—67 (1939).
- LEATHEM, J. H.: Growth of mammary glands of hypophysectomized rats following estrogen and lactogen administration. *Proc. Soc. exp. Biol. (N. Y.)* **59**, 122—124 (1945).
- LEONARD, S. L.: Lobule-alveolar growth of mammary glands of hypophysectomized female rats. *Proc. Soc. exp. Biol. (N. Y.)* **49**, 660—662 (1942).
- REIN, G.: Untersuchungen über die embryonale Entwicklungsgeschichte der Milchdrüse. *Arch. mikr. Anat.* **20**, 431—501 (1882); **21**, 678—694 (1882).
- REINECKE, E. P., MEITES, J., CAIRY, C. F., HUFFMAN, D. F.: Hormonal induction for lactation in sterile cows. In: *Proceedings annual meeting American Veterinary Medical Association*, 1952, p. 325—328, Atlantic City. Amer. Veterinary Med. Ass.
- RICHARDSON, K. C.: (a) Some structural features of the mammary tissues. *Brit. med. Bull.* **5**, 123—129 (1947).
- (b) Contractile tissues in the mammary gland with special reference to myo-epithelium in the goat. *Proc. roy. Soc. B* **136**, 30—45 (1949).
- (c) Measurement of the total area of secretory epithelium with lactatin mammary gland of the goat. *J. Endocr.* **9**, 170—184 (1953).
- (d) Mammary tumors and mammary gland development in normal and oestrogen-treated F₁ hybrids of strains C₃H/J and R III/An mice. *J. nat. Cancer Inst.* **36**, 1167—1187 (1966).
- (e) The acinar pattern in the mammary glandes of virgin mice at different ages. *J. nat. Cancer Inst.* **38**, 305—315 (1967).

- RIDDLE, O.: Prolactin invertebrate function and organization. *J. nat. Cancer Inst.* **31**, 1039—1110 (1963).
- The preparation, identification and assay of prolactin — a hormone of the anterior pituitary. *Amer. J. Physiol.* **105**, 191—216 (1933).
- BATES, R. W., DYKSHORN, S. W.: A new hormone of the anterior pituitary. *Proc. Soc. exp. Biol. (N. Y.)* **29**, 1211—1212 (1932).
- BRAUCHER, P. F.: Studies on the physiology of reproduction in birds. XXX. Control of the special secretion of the crop-gland in pigeons by an anterior pituitary hormone. *Amer. J. Physiol.* **97**, 617—625 (1931).
- RIEDEL, G.: Die Entwicklung und Entartung des elastischen Gewebes in der senilen Mamma. *Virchows Arch. path. Anat.* **256**, 242—267 (1925).
- ROSEN, S. W., GAHRES, E. E.: Nonpuerperal galactorrhoea and the contraceptive pill. *J. Obstet. Gynec.* **29**, 730—731 (1967).
- ROSENBURG, A.: Über menstruelle, durch das Corpus luteum bedingte Mamma-veränderungen. *Frankfurt. Z. Path.* **27**, 466—506 (1922).
- ROSS, R., KLEBANOFF, S.: Fine structural changes in uterine smooth muscle and fibroblasts in response to estrogen. *J. Cell Biol.* **32**, 155—167 (1967).
- SAAMELI, K.: Untersuchungen über den Blutspiegel und die Abbaugeschwindigkeit von Oxytocin. *Gynaecologia (Basel)* **152**, 329—332 (1961).
- SALTER, J., BEST, C. H.: Insulin as a growth hormon. *Brit. med. J.* **1953 II**, 353—359.
- SANDRITTER, W., FEDERLIN, K., PFEIFFER, E. F.: Quantitative histochemical studies on islet cells. In: *The structure and metabolism of the pancreatic islets*. Proc. 3rd. Internat. Symp. Stockholm, 1963. Oxford-London-Edinburgh-New York-Paris-Frankfurt: Pergamon Press 1964.
- SCHACHNER, S. H.: Galactorrhoea subsequent to contraceptive hormones. *New Engl. Med. J.* **275**, 1138—1141 (1966).
- SCHÄFER, A., BÄSSLER, R.: Vergleichende elektronenoptische Untersuchungen am Drüsenepithel und am sog. lobulären Carcinom der Mamma. *Virchows Arch. Abt. A Path. Anat.* **346**, 269—286 (1969).
- SCHAEFER, H. E., FISCHER, R.: Östrogenbedingte Induktion alkalischer Phosphatase in Fibroblasten des subkutanen Bindegewebes der Maus. *Acta endocr. (Kbh.)* **57**, 261—273 (1968).
- SCHAIRER, E.: Kernmessungen und Chromosomenzählungen an menschlichen Geschwülsten. *Z. Krebsforsch.* **43**, 1—38 (1936).
- SCHALTENBRAND, G.: *Die Nervenkrankheiten*. Stuttgart: Thieme 1951.
- SCHARF, G., LYONS, W. R.: Effects of estrone and progesterone on male rabbit mammary glands. II. Varying doses of estrone. *Proc. Soc. exp. Biol. (N. Y.)* **48**, 86—89 (1941).
- SCHIMMELBUSCH, C.: Das Cystadenom der Mamma. *Arch. klin. Chir.* **44**, 117—134 (1892).
- SCHIPP, R.: Der Feinbau filamentärer Strukturen im Endothel peripherer Lymphgefäße. *Acta anat. (Basel)* **71**, 341—351 (1968).
- SCHMIDT, HUGO: Über normale Hyperthelie menschlicher Embryonen und über die erste Anlage der menschlichen Milchdrüsen überhaupt. *Schwalbes morphol. Arb.* **7**, 157—199 (1897).
- SCHMITT, HEINRICH: Über die Entwicklung der Milchdrüse und die Hyperthelie menschlicher Embryonen. *Schwalbes morphol. Arb.* **8**, 236—303 (1898).
- SCHNURBUSCH, F.: Untersuchungen über die Morphologie der männlichen Brustdrüse während des Lebensablaufes als Grundlage für ein Studium der Gynäkomastie. *Frankfurt. Z. Path.* **62**, 402—418 (1951).
- SCHRIEVER, D.: Histochemische Untersuchungen am Bindegewebe der Mamma in physiologischen Funktionsphasen. Inaug.-Diss. Mainz, 1968.
- SCHULTZ, A.: Pathologische Anatomie der Brustdrüse. In: *Handbuch der speziellen pathologischen Anatomie und Histologie* von O. LUBARSCH und F. HENKE, Weibliche Geschlechtsorgane, 7. Bd., 2. Teil. Berlin: Springer 1933.

- SCHULZE, G.: Histochemische Untersuchungen am Bindegewebe der hormonal stimulierten Mamma. Inaug.-Diss. Mainz, 1968.
- SEGAL, S. J., SCHER, W.: Estrogenes, nuclei acids and protein synthesis in uterine metabolism. In: R. M. WYNN, Cellular biology of the uterus, p. 114—150. Amsterdam: North Holland publ. 1967.
- SEIFERT, G.: Über Gewebsreaktionen der menschlichen Brustdrüse bei Leukämien. Virchows Arch. path. Anat. **322**, 336—357 (1952).
- SELYE, H.: On the nervous control of lactation. Amer. J. Physiol. **107**, 535—538 (1934).
- Activity of progesterone in spayed female not pretreated with estrin. Proc. Soc. exp. Biol. (N. Y.) **43**, 343—344 (1940).
- (a) Stress and lactation. Rev. canad. Biol. **13**, 377—384 (1954).
- (b) The effect of cortisol upon the mammary glands. Acta endocr. (Kbh.) **17**, 394—401 (1954).
- BROWNE, J. S. L., COLLIP, J. B.: The effect of large doses of progesterone in the female rat. Proc. Soc. exp. Biol. (N. Y.) **34**, 472—474 (1936).
- MCEUEN, C. S., COLLIP, J. B.: Effect of testosterone on mammary gland. Proc. Soc. exp. Biol. (N. Y.) **34**, 201—203 (1936).
- SEMB, C.: Fibroadenomatosis cystica mammae. Acta chir. scand. **64**, Suppl. X, 1—483 (1928).
- SHORT, R. H. D.: Alveolar epithelium in relation to growth of the lung. Phil. Trans. B **235**, 35—86 (1951).
- SILVER, I. A.: Myoepithelial cells in the mammary and parotid glands. J. Physiol. (Lond.) **125**, 8—9 (1954).
- SMITH, TH. C.: The action of relaxin on mammary gland growth in the rat. Endocrinology **54**, 59—70 (1954).
- The effect of estrogen and progesterone on mammary gland growth in the rat. Endocrinology **57**, 33—43 (1955).
- Action of estrogen and progesterone on mammary nucleic acids and enzymes in rats. Endocrinology **65**, 51—55 (1959).
- BRAVERMAN, L. B.: The action of desoxycorticosterone acetate on the mammary gland of the immature ovariectomized rat. Endocrinology **52**, 311—317 (1953).
- RICHTERICH, B.: Synergism of estrogen and progesterone on mammary growth in guinea pigs. Endocrinology **63**, 89—98 (1958).
- SMITHCORS, J. F., LEONARD, S. L.: Limited effects of certain steroid hormones on mammary glands of hypophysectomized rats. Proc. Soc. exp. Biol. (N. Y.) **54**, 109—111 (1943).
- SOEMARWOTO, J. N., BERN, H. A.: The effect of hormones on the vascular pattern of the mouse mammary gland. Amer. J. Anat. **103**, 403—435 (1958).
- SPEERT, H.: The normal and experimental development of the mammary gland of the rhesus monkey with some pathological correlations. Contr. Embryol. Carneg. Inst. **32**, 9—65 (1948).
- SPELLACY, W. N., CARLSON, K. L., SCHADE, S. L.: Human growth hormone studies in patients with galactorrhea (Ahumada-del-Castillo-Syndrome). Amer. J. Obstet. Gynec. **100**, 84—89 (1968).
- SPULER, A.: Abriß der Entwicklungsgeschichte der Milchdrüse. In: Handbuch der Gynäkologie, hrsg. von W. STOECKEL, Bd. 1, S. 490—510. Berlin: Bergmann 1930.
- STEIN, O., STEIN, Y.: Formation of milk glycerides in lactating mice studied by electronmicroscopic autoradiography. Israel J. med. Sci. **2**, 773—778 (1966).
- STEINBECK, H.: Die Wirkung der verschiedenen Gestagene auf Morphologie und Funktion der Milchdrüse. In: Handbuch der experimentellen Pharmakologie, hrsg. von O. EICHLER, A. FARAH, H. HERKEN und A. D. WELCH, Bd. 22/2, S. 341—425. Berlin-Heidelberg-New York: Springer 1969.

- STÖCKER, E.: (a) Autoradiographische Untersuchungen zur Deutung der funktionellen Kernschwellung am exokrinen Pankreas. *Z. Zellforsch.* **57**, 47—62 (1962).
- (b) Autoradiographische Untersuchungen mit $^{12}\text{H}^3$ und $^{14}\text{C}^{14}$ markierten Aminosäuren zur Größe des nukleolären und zytoplasmatischen Eiweißstoffwechsels bei verschiedenen Zellarten von Maus und Ratte. *Z. Zellforsch.* **70**, 419—448 (1966).
- STRICKER, P.: Recherches expérimentales sur les fonctions du lobe antérieur de l'hypophyse: influence des extraits du lobe antérieur sur l'appareil génital de la lapine et sur la montée laiteuse. *Presse méd.* **37**, 1268—1271 (1929).
- GRUETER, F.: Action du lobe antérieur de hypophyse sur la montée laiteuse. *C. R. Soc. Biol. (Paris)* **99**, 1978—1980 (1928).
- SUCHENWIRTH, R., BUES, F.: Galaktorrhoe als Leitsymptom bei Hypophysenadenomen. *Endokrinologie* **41**, 66—75 (1961).
- SUETINA, J. A., CHENTSOV, S., CHENTSOV, Y., SMIRNOVA, J. O., SAMOILOV, W. J.: Action mechanism of estrogens and progesteron on the mammary glands. *Arh. Patol. (Moskva)* **28**, 16—22 (1966).
- SYKES, J. F.: Hormonal development of mammary tissue in dairy heifers. *J. Dairy Sci.* **34**, 1174—1179 (1951).
- WRENN, T. R.: Hormonal development of the mammary gland of dairy heifers. *J. Dairy Sci.* **33**, 194—204 (1950).
- SYLVEN, B.: Über die Elektivität und Fehlerquellen der Schleimfärbung mit Mucicarmin im Vergleich mit metachromatischer Färbung. *Virchows Arch. path. Anat.* **303**, 280—394 (1938).
- TAKAHASHI, N.: Electron microscopic studies on the ectodermal secretory glands in man. The fine structure of the apocrine sweat glands with special reference to the myoepithelium. *Bull. Tokyo med. dent. Univ.* **4**, 259—269 (1957).
- Electron microscopic studies on the extodermal secretory glands in man. II. The fine structures of the myoepithelium in the human mammary and salivary glands. *Bull. Tokyo med. dent. Univ.* **5**, 177—192 (1958).
- TALWALKER, P. K.: Mammary lobulo-alveolar growth in adreno-ovariectomized rats following transplantation of "mammatropic" pituitary tumor. *Proc. Soc. exp. Biol. (N. Y.)* **117**, 121—124 (1964).
- MEITES, J.: Mammary lobulo-alveolar growth induced by anterior pituitary hormones in adreno-ovariectomized and adreno-ovariectomized-hypophysectomized rats. *Proc. Soc. exp. Biol. (N. Y.)* **107**, 880—883 (1961).
- NICOLL, C. S., MEITES, J.: Induction of mammary secretion in pregnant rats and rabbits by hydrocortisone acetate. *Endocrinology*, **69**, 802—808 (1961).
- TAMARIN, A.: Myoepithelium of rat submaxillary gland. *J. Ultrastruct. Res.* **16**, 320—338 (1966).
- TANDLER, B.: Ultrastructure of the human submaxillary gland. *Z. Zellforsch.* **68**, 852—863 (1965).
- TAYLOR, H. C.: (a) The relation of chronic mastitis to certain hormones of the ovary and pituitary and to coincident gynecological lesions. *Surg. Gynec. Obstet.* **62**, 129—148 (1936).
- (b) The relation of chronic mastitis to certain hormones of the ovary and pituitary and to coincident gynecological lesions. *Surg. Gynec. Obstet.* **62**, 562—584 (1936).
- WALTMAN, C. A.: Hyperplasias of the mammary gland in the human being and in the mouse. *Arch. Surg.* **40**, 733—820 (1940).
- TERZAKIS, I. A.: The ultrastructure of monkey eccrine sweat glands. *Z. Zellforsch.* **64**, 493—509 (1964).
- THÖLEN, H.: Das embryonale und postnatale Verhalten der männlichen Brustdrüse beim Menschen. I. Das Mammaorgan beim Embryo und Säugling. *Acta anat. (Basel)* **8**, 201—235 (1949).
- THOENES, W.: Mikromorphologie des Nephron nach temporärer Ischämie. Stuttgart: Thieme 1964.

- TRAURIG, H.: (a) Cell proliferation in the mammary gland during late pregnancy and lactation. *Anat. Rec.* **157**, 489—504 (1967).
- (b) A radioautographic study of all proliferation in the mammary gland of the pregnant mouse. *Anat. Rec.* **159**, 239—248 (1967).
- TRENTIN, J. J.: The experimental development of the mammary gland with special reference to the interaction of the pituitary and ovarian hormones. *Mo. agric. Exp. Sta. Res. Bull* Nr. 418 (1948).
- TURNER, C. W.: Effect of adrenalectomy on the mammary gland of the castrated and estrogen treated male rat. *Endocrinology* **41**, 127—134 (1947).
- TREVES, N.: Gynecomastia. The origins of mammary swelling in the male: an analysis of 406 patients with breast hypertrophy, 525 with testicular tumors and 13 with adrenal neoplasma. *Cancer (Philad.)* **11**, 1082—1102 (1958).
- TUCKER, H. A.: (b) Nuclei acid content of mammary glands of lactating rats. *Proc. Soc. exp. Biol. (N. Y.)* **112**, 409—412 (1963).
- (d) Nuclei acid of rat mammary glands during post-lactational involution. *Proc. Soc. exp. Biol. (N. Y.)* **112**, 1002—1004 (1963).
- REECE, R. P.: (a) Nuclei acid content of mammary glands of pregnant rats. *Proc. Soc. exp. Biol. (N. Y.)* **112**, 370—372 (1963).
- — (c) Nuclei acid content of mammary gland of rats lactating 41 and 61 days. *Proc. Soc. exp. Biol. (N. Y.)* **112**, 688—690 (1963).
- TURNER, C. W.: The mammary gland. I. The anatomy of the udder of cattle and domestic animals. Columbia: Lucas Brothers 1952.
- GOMEZ, E. T.: The experimental development of the mammary gland. I. The male and female albino mouse. II. The male and female guinea pig. *Mo. agric. Exp. Sta. Res. Bull.* Nr. 206 (1934).
- YAMAMOTO, H., RUPPERT, H. L.: The experimental induction of growth of the cow's udder and the initiation of milk secretion. *J. Dairy Sci.* **39**, 1717—1729 (1956).
- URBAN, J. A., ADAIR, F. E.: Sklerosing adenosis. *Cancer (Philad.)* **2**, 625—634 (1949).
- VERLEY, J. M., HOLLMANN, K. H.: Synthèse et réabsorption des protéines dans la glande mammaire en stase étude autoradiographique au microscope électronique. *Z. Zellforsch.* **75**, 605—610 (1966).
- VERNE, J.: État actuel de la cytochimie de la glande mammaire. *Cell. int. Cent. nat. Rech. sci.* **32**, 59—66 (1951).
- VERONESI, U., CANDIANI, M. A.: La glandola mammaria muliebre nella senescenza. *Biol. lat. (Milano)* **8**, 7—100 (1955).
- VIGNEAUD, P. G. DU, RESSLER, C., SWAN, J. M., ROBERTS, C. W., KATSOYAMIS, P. G., GORDON, S.: The synthesis of an octapeptide amide with the hormonal activity of oxytocin. *J. Amer. chem. Soc.* **75**, 4879—4880 (1953).
- VIGNEAUD, V. DU, LAWLER, H. C., POPENOE, E. A.: Enzymatic clearance of glycine-amide from vasopressin and a proposed structure for this pressor-antidiuretic hormone of the posterior pituitary. *J. Amer. chem. Soc.* **75**, 4880—4881 (1953).
- VILLANI, G., ZANELLA, E.: Il tessuto elastico nei tumori e in altre forme patologiche della mammella. *Arch. De Vecchi Anat. pat.* **17**, 537—552 (1951).
- VITRY, G.: Modification histochimique de la substance fondamentale du tissu conjonctif, de la tétine du cobaye sans l'action de diverse hormones sexuelles. *C. R. Soc. Biol. (Paris)* **147**, 124—126 (1953).
- VOGLER, E.: Über das basilare Helle-Zellen-Organ der menschlichen Brustdrüse. *Klin. Med. (Wien)* **2**, 159—167 (1947).
- VOLKMANN, H.: Zahlen und Daten zur Funktion der Milchdrüsen. Zusammenstellung und Tabelle (Beilage). *Med. Klin.* **39** (1951).
- VOSS, H. E.: Die hormonale Regelung der Laktation. *Dtsch. med. Wschr.* **83**, 288—291, 328—331 (1958).

- WAGENEN, G. VAN, FOLLEY, S. J.: Effect of androgens on mammary gland of female rhesus monkey. *J. Endocr.* **1**, 367—372 (1939).
- WATTENWYL, H. v.: Tierexperimentelle Untersuchungen über die Wirkung langdauernder Follikelhormonapplikation und die hormonale Tumorentstehung. Inaug.-Diss. Basel, 1944.
- WATZKA, M.: Zellen mit speziellen Funktionen. In: Handbuch der allgemeinen Pathologie, hrsgg. von F. BÜCHNER, E. LETTERER und R. ROULET, Bd. II/1. Berlin-Göttingen-Heidelberg: Springer 1955.
- WAUGH, D., HOEVEN, E. VAN DER: Fine structure of the human adult female breast. *Lab. Invest.* **11**, 220—228 (1962).
- WEBER, A. T., KITCHELL, R. L., SAUTTER, I. H.: Mammary gland studies. I. The identity and characterization of the smallest lobule unit in the udder of the dairy cow. *Amer. J. vet. Res.* **16**, 255—263 (1955).
- WEBER, W.: Zur Histologie und Cytologie der Kropfmilchbildung der Taube. *Z. Zellforsch.* **56**, 247—276 (1962).
- WEICHERT, C. K., BOYD, R. W., COHEN, R. S.: A study of certain endocrine effects in the mammary glands of female rats. *Anat. Rec.* **61**, 21 (1934).
- WELLINGS, S. R., NANDI, S.: Electron microscopy of induced secretion in mammary epithelial cells of hypophysectomized-ovarectomized-adrenalectomized BALB/c Crgl mice. *J. nat. Cancer Inst.* **40**, 1245—1258 (1968).
- PHILP, J. R.: The function of the Golgi apparatus in lactating cells of the BALB/c Crgl mouse. An electron microscopic and autoradiographic study. *Z. Zellforsch.* **61**, 871—882 (1964).
- WENNER, R.: Physiologische und pathologische Lactation. *Arch. Gynäk.* **204**, 171—206 (1966).
- WERNER, K. H.: Über die Wirkung des Follikelhormons auf die Milchdrüsen kastrierter Ratten. Diss. Leipzig 1938.
- WIDER, J. A., MARSHALL, J. R., ROSS, G. T.: Familial galactorrhoea in three sisters with oligo-ovulation. *J. Amer. med. Ass.* **209**, 669—671 (1969).
- WILLIAMS-ASHMAN, H. G.: Androgenic control of nucleic acid and protein synthesis in male accessory genital organs. *J. cell. comp. Physiol.* **66**, 111—124 (1965).
- WYK, J. J. v., GRUMBACH, M. M.: Syndrom of precocious menstruation and galactorrhea in juvenil hypothyroidism: an example of hormonal overlap in pituitary feedback. *J. Pediat.* **57**, 416—435 (1960).
- YAMAMOTO, H., TURNER, C. W.: Experimental mammary gland growth in rabbits by estrogen and progesterone. *Proc. Soc. exp. Biol. (N. Y.)* **92**, 130—132 (1956).
- ZAKS, M. G.: The motor apparatus of the mammary gland, ed. by A. T. COWIE. Edinburgh and London: Oliver and Boyd 1962.
- ZARZYCKI, L., PERYT, A., KLUBINSKA, B., HJAC, T., ZAK, K.: Histochemische Untersuchungen über den Involutionsmechanismus der Milchdrüse. *Histochemie* **18**, 314—320 (1969).
- ZONDEK, B., BROMBERG, Y. M., ROZIN, S.: An anterior pituitary hyperhormotropic syndrome. *J. Obstet. Gynaec. Brit. Emp.* **58**, 525—537 (1951).